

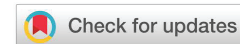**Received:** 29 October, 2022  
**Accepted:** 08 December, 2022  
**Published:** 09 December, 2022

**\*Corresponding authors:** Ashwini K, PG Student, Department of Orthodontics, Shri Dharmasthala Manjunatheshwara University, College of Dental Sciences and Hospital, Dharwad, India, E-mail: ashkimiorth10@gmail.com

**Keywords:** Pharyngeal airway space; Upper airway space; Cleft lip; Cleft palate; Camouflage; Maxillary advancement

**Copyright License:** © 2022 Pragnesh KJ, et al. This is an open-access article distributed under the terms of the Creative Commons Attribution License, which permits unrestricted use, distribution, and reproduction in any medium, provided the original author and source are credited.

<https://www.peertechzpublications.com>



## Research Article

# Cephalometric evaluation and comparison of upper pharyngeal airway space in cleft lip and cleft palate patients treated with maxillary advancement and camouflage

Kairav Joshi Pragnesh<sup>1</sup>, Shashikumar B<sup>2</sup>, Anand K Patil<sup>3</sup>,  
Roopak D Naik<sup>4</sup> and Ashwini K<sup>5\*</sup>

<sup>1</sup>Practitioner, Surat, India

<sup>2</sup>Associate Professor, Department of Orthodontics, Shri Dharmasthala Manjunatheshwara University, College of Dental Sciences and Hospital, Dharwad, India

<sup>3</sup>Professor, Department of Orthodontics, Shri Dharmasthala Manjunatheshwara University, College of Dental Sciences and Hospital, Dharwad, India

<sup>4</sup>Professor and Head of the Department, Department of Orthodontics, Shri Dharmasthala Manjunatheshwara University, College of Dental Sciences and Hospital, Dharwad, India

<sup>5</sup>PG Student, Department of Orthodontics, Shri Dharmasthala Manjunatheshwara University, College of Dental Sciences and Hospital, Dharwad, India

## Abstract

**Introduction:** Pharyngeal airway space has become an important criterion for diagnosis and treatment planning and this has led to a paradigm shift towards soft tissue evaluation for orthodontic diagnosis and treatment planning. The aims and objectives of the study were to evaluate and compare upper pharyngeal airway space in Cleft Lip & Cleft Palate patients who underwent orthodontic treatment under different treatment modalities like Camouflage treatment & Maxillary Advancement.

**Methods:** This is a retrospective cephalometric study in which 20 Pre-treatment Cephalograms and 20 Post-treatment Cephalograms of Cleft Lip and Palate patients were taken. Orthodontic treatment involving Camouflage therapy and Maxillary Advancement were studied in each respective group. The Cephalogram was traced on Matt acetate paper and the pharyngeal airway space was measured using the McNamara analysis method.

**Results:** Statistically significant difference was observed in the Pre-treatment and Post-treatment mean values in both groups, where the Post-treatment mean was higher than the Pre-treatment means in both groups. A highly significant mean was noted in the Cleft Surgical group as compared to the Camouflage (xiii) group, where, the post-treatment upper airway mean was higher in the Cleft Surgical group than the Cleft Camouflage group.

**Conclusion:** There is a significant increase in upper pharyngeal airway space in patients with CLCP treated with Maxillary Advancement and Camouflage modality. The significance is comparatively more in the Maxillary Advancement group than in the Camouflage group.

## Introduction

The pharynx, a tube-like structure is located behind the nasal cavity, oral cavity, and larynx. There are 3 parts of the pharynx namely the nasopharynx, oropharynx, and laryngopharynx. Reduced pharyngeal airway passage in any part of the pharynx can lead to Obstructive Sleep Apnea. Patients with reduced oropharyngeal airway space are associated with a high risk of Obstructive Sleep Apnea.

The pharyngeal airway evaluation is an important aspect of orthodontic diagnosis as well as treatment planning.

Pharyngeal space size is determined primarily by the relative growth and size of soft tissues surrounding the dentofacial skeleton [1].

Pharyngeal airway space is evaluated by different procedures like lateral Cephalogram, 3-Dimensional methods like Cone Beam Computer Tomography (CBCT), Magnetic Resonance Imaging (MRI) Real-Time, Cine-CT (Cine Fluoroscopy), and Electron Beam Computed Tomography (EBCT).

Craniofacial anomalies, including mandibular retrognathism or maxillary retrognathism, short mandibular corpus, and backward and forward rotation of the mandible, may lead to the reduction of the pharyngeal airway passage [2].

The Orofacial clefts are congenital deformities that manifest at birth. Orofacial clefts are the most frequently occurring craniofacial birth defects.

Cleft lip and palate frequently produce significant nasal deformities such as the deviated septum, vomerine spurs, and atresia of nostrils, as well as maxillary growth deficits that alter the nasal floor. These abnormalities tend to reduce the size of the nasal airway [3].

It has been reported that Cleft Lip and Palate patients have a reduced nasal airway as compared with normal subjects and the incompetent nasal airway predisposes cleft lip and palate patients to oral breathing [4].

There has been no literature that has compared the pharyngeal airway dimensional changes in detail in cleft lip and cleft palate patients treated with different surgical and camouflage methods. In order to maintain proper airway space during and after treatment, the outcomes of different treatment modalities have to be evaluated.

Hence, this study is aimed at comparing the upper pharyngeal airway changes in cleft patients treated with maxillary advancement surgery and camouflage.

## Maxillary advancement surgery

Orthognathic surgery on the maxilla such as maxillary advancement surgery can have a significant effect on the internal and external nasal form and function of cleft patients. Patients with repaired cleft lips and palate often have nasal airway obstruction which can be corrected [5].

Maxillary advancement is an Orthognathic surgical procedure that is done to bring the maxilla more dorsally to correct various dental abnormalities like reverse overjet, hypoplastic maxilla, etc. It is a common treatment option for treating CLCP patients as many CLCP patients have an underdeveloped maxilla.

## Maxillary advancement surgical procedure

The patient is placed in a supine position with a shoulder roll for a neutral head position. Nasotracheal intubation is preferred in these patients so that occlusion can be checked without difficulty. Local anesthesia is then injected into the gingivobuccal sulcus of the upper lip to help with hemostasis. Once through the mucosa and into the loose areolar tissue in the submucosal plane, dissection should proceed directly to the bone. The incision is made from the first molar to the first molar, to expose both the lateral and medial buttresses of the maxilla.

When the periosteum is identified, it should be scored with electrocautery for the entire length of the incision. Subperiosteal dissection with an elevator is performed to expose the anterior surface of the maxilla. Dissection around the level of the piriform aperture should be mindful of the nasal mucosa and lining. The lateral dissection should end once the pterygomaxillary junction is encountered.

When designing the osteotomy, care should be taken to avoid the tooth roots. Using the maxillary canine as the longest tooth root reference (26 mm), the apices of the other teeth can be avoided. At the level of the piriform, the osteotomy should always be performed below the level of the inferior turbinate to avoid damage to the nasolacrimal system.

The osteotomy is made with a reciprocating saw at the lateral maxillary buttress and directed to the ipsilateral piriform rim. The same osteotomy is performed on the contralateral side. A thin osteotome is then used to complete the posterior osteotomies of the lateral and medial maxillary buttresses. A U-shaped osteotome is used to separate the nasal septum from the maxilla. The posterior maxillary wall is then fractured with an osteotome. Lastly, the pterygomaxillary junction should be separated with curved osteotomes. By placing a finger inside the mouth and feeling the hamulus, the medial extent of the osteotomy can be palpated to ensure the proper position. Once the osteotomies are completed, the down fracture is performed with digital pressure. If digital pressure does not complete the osteotomy, then a thorough interrogation of the previous osteotomies should be performed. The down fracture should be easy and should not require a large amount of force. Excessive force can cause unfavorable fractures and complications [6].

The desired movements are made in relation to the external reference points measured preoperatively. If a surgical splint has been fashioned preoperatively, it is then used to position the maxilla by placing the patient in maxillomandibular fixation (MMF).

## Indications of maxillary advancement surgery

1. Patients presenting a dental and/or skeletal Class III
2. Patients in Class I or in dental Class II and Class III present excessively-retrusive maxillary arches.
3. Vertical maxillary excess
4. Midline discrepancies/asymmetries
5. Apertognathia/open bite
6. The absolute transverse arch discrepancy
7. Dual or multi-planar occlusion
8. Severe maxillary atrophy (in conjunction with bone grafting)

Patients presenting significant class III malocclusion as well as a narrow dental arch and palatal collapse in Oro-facial cleft patients. If left untreated, the maxillary hypoplasia can lead to superior rotation of the mandible, reducing the facial height and upwardly tilting the occlusal plane.

## Camouflage therapy

Camouflage therapy in cleft patients wherein patients are undergoing fixed orthodontic mechanotherapy (along with maxillary expansion, extraction of teeth, two-phase therapy, etc) has an important impact on upper airway dimension because of transverse movements of lateral walls of the nose [7]. Thus, it would be beneficial to evaluate the airway dimensions for future treatments.

### Indications of camouflage therapy

1. Skeletal class III malocclusion due to maxillary retrognathia
2. Skeletal class III malocclusion due to mandibular prognathism
3. Skeletal class III malocclusion due to both maxillary retrognathia and mandibular prognathism.

## Orthodontic treatment and its effect on pharyngeal airway

A study was by Ucar F, et al. to test the null hypothesis that there are no significant differences in craniofacial structures and orofacial airway dimension in subjects with Class I malocclusion and different growth patterns. Lateral cephalometric radiographs of 31 low-angle, 40 high-angle, and 33 normal growth subjects with Class I malocclusion were examined. It was concluded by rejecting the null hypothesis as there was a significant difference in craniofacial morphology and orofacial airway dimensions of Class I subjects with different growth patterns [1].

A study was conducted by Joseph A, et al. to compare the dimensions of the nasopharynx, oropharynx, and hypopharynx of persons with hyperdivergent facial types and

neurodivergent facial types. Lateral cephalometric records of a population with a neurodivergent facial pattern and a group with a hyperdivergent facial pattern as evidenced by increased mandibular plane angle were used to compare soft tissue airway dimensions. It was observed that the hyperdivergent group had a narrower anteroposterior pharyngeal dimension than the neurodivergent control group. The narrower anteroposterior dimension of the airway in hyperdivergent patients are maybe attributable to skeletal features common to such patients, that is, retrusion of the maxilla and the mandible and vertical maxillary excess [2].

A study by Naoko Imamura was conducted to compare the sizes of adenoidal tissues & upper airways in 90 juveniles and 40 adolescents, with & without Cleft Lip and Palate. Two paired groups were made, one with Cleft lip and palate and one control group. Digital cephalograms were used to determine the measurements. It was concluded that there was a larger adenoidal tissue size in the Cleft lip and palate- juvenile group than in the corresponding control group and there was a more restricted upper airway in the Cleft lip and palate juvenile group than in the corresponding juvenile control group [8].

## The pharyngeal airway changes have been measured using McNamara's analysis [9]

The most common method for analyzing the airway for the orthodontist is the lateral cephalogram head film. Bushey [10] review -the "state of the art" for measuring the adenoids and airway using lateral cephalograms [11]. In this article, they described 2 sets of measurements, one developed by Linder-Aronson and Henrickson [12] and the other by Schulhof [13].

Airway impairment can be measured by 2 methods. The upper airway is measured from a point on the posterior border of the soft palate to the closest point on the posterior pharyngeal wall. The average is 15 mm - 20 mm according to Mc Namara [9]. According to a study by Ann Arbon upper airway is 17.4 mm which increases with age. Lower Pharyngeal airway space is measured from the intersection of the posterior border of the tongue and the inferior border of the mandible to the closest point on the posterior pharyngeal wall. The average is 10 mm - 12 mm according to Mc Namara. According to Ann Arbon average value is the same as Mc Namara and does not change with age.

According to Sullivan, et al. [14], due to obstruction of the upper pharyngeal airway, there will be arterial oxygen desaturation and sleep fragmentation which will further lead to Obstructive Sleep Apnea (OSA).

Reports given by Warren, Duany, and Fischer, it is said that nasal airway resistance is higher in the cleft population and it is attributed to deformities of the nose and growth deficits of the maxilla, both of which contribute to reducing the size of the nasal airspace [15].

In a study done by Fazal, et al. [16], they concluded that there was an overall reduction in nasal cavity volume in patients with cleft lip and palate compared to non-cleft patients.

When there is a decrease in pharyngeal airway space, it might lead to obstructive sleep apnea [17]. The demand for integrating treatment of sleep apnea into the orthodontic practice shortly will be driven by the need of the societies as some of our patients will be shortly coming into our offices aware of sleep apnea.

Due to the proven airway resistance in CLCP patients, it is important to compare the Pre-treatment and Post-treatment outcomes of the patients to evaluate the final result that is achieved.

### Aims & objectives

The aims and objectives of the study were to evaluate and compare the following parameters in Cleft Lip & Cleft Palate patients who underwent orthodontics treatment under different treatment modules

- 1) To measure the pharyngeal airway space in patients with Cleft Lip & Cleft Palate.
- 2) To evaluate the cephalometric changes in upper pharyngeal airway space in cleft lip and palate patients, treated with maxillary advancement surgery and camouflage therapy.
- 3) To compare the airway space change between each modality of therapy.

### Materials and methods

This is a retrospective cephalometric study in which 20 Pre-treatment and 20 Post-treatment cephalograms of cleft lip and palate patients in each group were taken. Orthodontic treatment involving camouflage and maxillary advancement surgery in cleft lip and palate patients will be studied. The sample size of the study is 40 subjects which comprise 20 subjects under each group; where 20 patients are planning to undergo camouflage therapy and 20 patients are planning for or have undergone maxillary advancement surgery.

Records were obtained from the Department of Orthodontics and Dentofacial Orthopedics of SDM College of Dental Sciences, Dharwad, and Karnataka, India.

#### The inclusion criteria

1	Patients in the age group of 16-22 years.
2	Patients who have undergone camouflage therapy.
3	Patients who have undergone Maxillary Advancement surgery.

#### The exclusion criteria

1	Patients with syndromic cleft lip and palate.v
2	Patients with hyperplasia of adenoids, and tonsillitis.

All lateral cephalometric radiographs had been taken using conventional methods in the natural head position with the Frankfurt Horizontal plane parallel to the floor. The magnification ratio of the cephalometric machine was 1:1.

McNamara's Airway Analysis was used in this study where

*McNamara's upper pharynx dimension:* The minimum distance between the posterior borders of the upper soft palate to the corresponding closest point on the posterior pharyngeal wall.

### Statistical methods

**Statistical analysis:** The data that was obtained were analyzed statistically with the software, Statistical Package for Social Sciences (SPSS) version 21.0.

The following statistical formulae were used in the data analysis.

**Mean:** It is the measure of the central tendency of a random variable characterized by its distribution. It was calculated by the formula:

$$\bar{X} = \frac{x_1 + x_2 + \dots + x_n}{n} = \frac{\sum_{i=1}^n x_i}{n}$$

In which,

$x$  = mean

$x$  = variables

$\Sigma x$  = summation of  $x$  values

$n$  = sample size

**Standard deviation:** It is a measure for quantifying the degree of changes in a group of data values. It was calculated by the formula:

$$s = \frac{\sqrt{\sum_{i=1}^n (x_i - \bar{x})^2}}{n - 1}$$

In which,

$s$  = standard deviation

$n$  = sample size

$x$  = mean

$x_i$  = each variable of the data

The data was presented as Mean and Standard deviation (SD).

- Independent t test is done for comparing the inter group significance of treatment with Maxillary Advancement group and Cleft Camouflage group. Paired t test is done for comparing the intragroup significance of pre and post treatment results in Maxillary Advancement group and Cleft Camouflage group.
- The obtained results were presented in both, a tabular format, as well as in a graphical format, in order to compare and view the results in a more convenient and comprehensible way.





### Sample size estimation

The following formula was used for determining the sample size for the present study in each group.

$$n = 2 \left[ \frac{(z_{\alpha} - Z_{1-\beta})S}{d} \right]^2$$

N=16. Thus, corroborating the above values the sample size for the present study was found to be 20 in each group. Therefore, a total of 80 subjects with 20 samples in each group were chosen for this study.

### Results

The table below shows the descriptive statistics of both the groups considered in the study, i.e Cleft camouflage and Cleft Surgical, which included 20 patients' Pre-treatment and Post-treatment measurements in each group Table 1.

It can be inferred from the above statistics

- a) The Post-treatment mean in Cleft Camouflage group was higher than that of the Pre-treatment mean.
- b) The Post-treatment mean in Cleft Surgical group was higher than that of the Pre-treatment mean.
- c) The standard deviation is greater in the Post-treatment Cleft Camouflage group than that of the Post-treatment Cleft Surgical group Table 2.
- Upon doing an independent sample t test, it can be said that there was a statistically significant higher Pre-treatment mean value in Cleft Surgical group than Cleft Camouflage group.
- The post treatment mean value was also highly significant in Cleft Surgical group than Cleft Camouflage group
- P value in the Post-treatment Cleft camouflage and Cleft surgical group is 0.001 which is lesser than 0.05 which is the set statistical value of significance Table 3.

The above inference can be understood with clarity by the chart and the graph below Graph 1.

- Paired sample t test displayed a statistical significant higher mean upper pharyngeal space seen in the post treatment when compared to Pre-treatment among maxillary advancement surgery [(Post-Treatment (18.1 ± 3.0) > Pre-Treatment (16.6 ± 3.9); t = -2.303; p = 0.033)] and camouflage therapy [(Post-Treatment (13.6 ± 3.8) > Pre-Treatment (12.9 ± 3.9); t = -2.488; p = 0.022)].
- The above results suggests that there was a higher significant post treatment upper pharyngeal airway space in Cleft Surgical group as compared to Cleft Camouflage group.

**Table 1:** Descriptive statistics.

		N	Mean	SD
Cleft Camouflage	Pre Treatment	20	12.90	3.88
	Post Treatment	20	13.58	3.83
Cleft Surgical	Pre Treatment	20	16.58	3.85
	Post Treatment	20	18.13	2.96
Total	Pre Treatment	40	14.74	4.24
	Post Treatment	40	15.85	4.09

**Table 2:** The table below shows the comparison of upper pharyngeal airway space at Pre-treatment for Cleft Camouflage and Cleft Surgical group and at Post-treatment for Cleft Camouflage and Cleft Surgical group.

	Groups	N	Mean	SD	t Value	P Value
Pre Treatment	Cleft Camouflage	20	12.9	3.9	-3.007	0.05*
	Cleft Surgical	20	16.6	3.9		
Post Treatment	Cleft Camouflage	20	13.6	3.8	-4.204	0.001*
	Cleft Surgical	20	18.1	3.0		

\*Statistical Significance set at 0.05

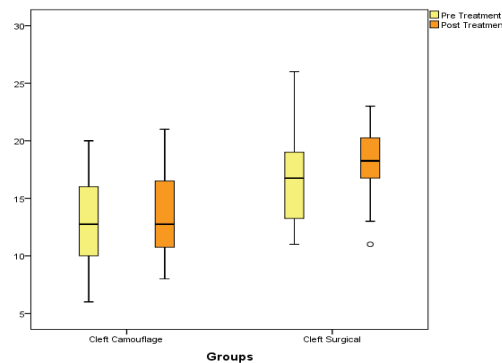
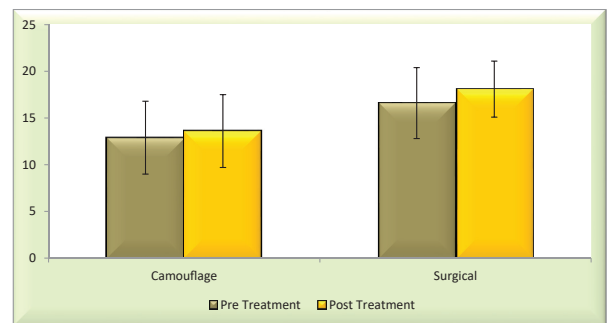
N: Number of samples; SD: Standard Deviation

**Table 3:** Comparison of Cephalometric changes in upper pharyngeal airway space in cleft lip and palate patients treated before and after treated with maxillary advancement surgery and camouflage therapy.

		N	Mean	SD	t Value	p value
Cleft Camouflage	Pre Treatment	20	12.9	3.9	-2.303	0.033*
	Post Treatment	20	13.6	3.8		
Cleft Surgical	Pre Treatment	20	16.6	3.9	-2.488	0.022*
	Post Treatment	20	18.1	3.0		

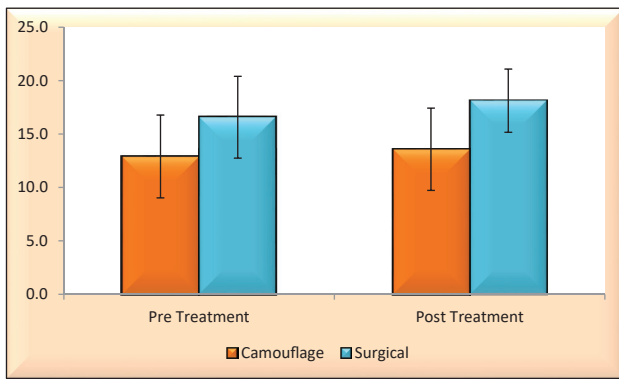
\*Statistical Significance set at 0.05

N: Number of samples; SD: Standard Deviation



**Figure 1:** Distribution of cephalometric changes in upper pharyngeal airway space in cleft lip and palate patients treated with maxillary advancement surgery and camouflage therapy at pre and post treatment.

The above inference can be understood with clarity by the chart below Graph 2.



**Figure 2:** Distribution of Cephalometric changes in upper pharyngeal airway space in cleft lip and palate patients treated before and after treated with maxillary advancement surgery and camouflage therapy.

## Discussion

The pharyngeal airway space is an important part of Stomatognathic system. As there is a paradigm shift towards soft tissue evaluation for orthodontic diagnosis and treatment planning, evaluation of pharyngeal airway is also an important aspect.

Patients suffering from Cleft Lip and Cleft Palate, either unilateral or bilateral, are generally treated with 2 different treatment modalities in Orthodontics. Cleft camouflage is a treatment modality wherein the patient is subjected to extraction or non-extraction line of treatment as the severity of the maxillary deficiency is not that high and can be resolved with maxillary expansion followed by fixed mechanotherapy. Whereas, in patients, where the maxillary deficiency is too severe, it is advised to go further ahead with maxillary advancement surgery. Maxillary advancement is preceded by maxillary expansion and fixed mechanotherapy. With the surgical intervention, the reverse overjet is corrected and gives a facial normalcy to the cleft affected patients. Thus, evaluation of pharyngeal airway space is an important aspect for diagnosis and treatment planning of a patient [18].

In the study done, the Post-treatment mean in Cleft Camouflage group and Cleft Surgical group was higher than that of the Pre-treatment mean. The standard deviation is greater in the Post-treatment Cleft Camouflage group than that of the Post-treatment Cleft Surgical group.

Paired sample t test displayed a statistical significant higher mean upper pharyngeal space seen in the post treatment when compared to Pre-treatment among maxillary advancement surgery [(Post-Treatment ( $18.1 \pm 3.0$ ) > Pre-Treatment ( $13.6 \pm 3.9$ );  $t = -2.303$ ;  $p = 0.033$ )].

Paired sample t test displayed a statistical significant higher mean upper pharyngeal space seen in the post treatment when compared to Pre-treatment among camouflage therapy [(Post-Treatment ( $13.6 \pm 3.8$ ) > Pre-Treatment ( $12.9 \pm 3.9$ );  $t = -2.488$ ;  $p = 0.022$ )].

P value in the Post-treatment Cleft camouflage and Cleft surgical group is 0.001 which is lesser than 0.05 which is the

set statistical value of significance, hence telling that there is increase in upper pharyngeal space post Camouflage and Surgery in Cleft lip and Cleft palate patients.

The above results suggests that there was a higher significant post treatment upper pharyngeal airway space in Cleft Surgical group as compared to Cleft Camouflage group.

According to Sullivan, et al. [14], due to obstruction of upper pharyngeal airway there will be arterial oxygen desaturation and sleep fragmentation which will further lead to Obstructive Sleep Apnea (OSA).

As per reports given by Warren, Duany and Fischer, it is said that the nasal airway resistance is higher in the cleft population and it is attributed to deformities of the nose and growth deficits of the maxilla, both of which contribute in reducing the size of the nasal airspace [15-37].

A study done by Farzal, et al. [16], they concluded that there was an overall reduction in nasal cavity volume in patients with cleft lip and palate compared to non-cleft patients.

## Limitations of the study

The limitations of the study are

1. In cephalogram only 2-dimensional view of 3-dimensional object can be obtained. Hence 3 dimensional methods can be used to get more accurate and precise readings and values.
2. There can be errors in identification of landmarks. Thus reliability of cephalometrics comes down.
3. Errors can be made during tracing procedures.
4. Assumptions: Various things are "assumed" in cephalometrics. a) Symmetry: The various analysis done on lateral projections are based on the assumptions that the patient does not have any skeletal asymmetry then the results of the analysis may not be accurate. Analysis of postero-anterior projections can avoid the above fallacy.
5. A correct occlusal and postural position is important in the accuracy of the cephalogram. Fallacy of false precision It is found that when a person takes a series of cephalogram of the head of the same person and does the tracing, locates the land marks and calculates; various angles measured showed a standard error of 1:5 that is each time it is slightly different.
6. Fallacy of ignoring the patient: The cephalometric values should not be taken as fixed goals. Sometimes certain values of a given patient may vary from the mean value. But it may not be an indication for treatment. Thus the patient should be analyzed individually before a treatment plan is laid. Just because the values differ it doesn't mean that treatment is required. If functions and esthetics are satisfied any deviations from normal of the cephalometrics value can be ignored.



7. Only linear measurements can be considered in the lateral cephalogram.
8. The volume of pharyngeal airway could not be measured.

To overcome the above limitations of the study, three dimensional methods can be used to get more accurate and precise readings and values.

## Conclusion

Current orthodontic practice has seen an important shift towards the consideration of the soft tissues. The pharyngeal airway evaluation is an important aspect of orthodontic diagnosis as well as treatment planning. Literature suggests that the pharyngeal airway dimensions in subjects with Cleft Lip and Palate patients are relatively narrower than normal non cleft subjects.

There has been no study which has compared the Pre-treatment and Post-treatment pharyngeal airway dimensional changes in detail in the Cleft Lip and Palate patients treated with different treatment modalities like Camouflage Therapy and Orthognathic surgical approach. In order to maintain proper airway space during and after treatment, the outcomes of these two different treatment modalities have to be evaluated.

The conclusion of the study can be put forth as

- There is a significant increase in upper pharyngeal airway space in patients with CLCP treated with Maxillary Advancement and Camouflage modality.
- However from the results that were obtained. On comparing both the groups, Maxillary Advancement (Cleft Surgical) had a higher significant post treatment upper airway mean as compared to the post treatment mean of the Cleft Camouflage group.

## References

1. Ucar FI, Uysal T. Orofacial airway dimensions in subjects with Class I malocclusion and different growth patterns. *Angle Orthod.* 2011 May;81(3):460-8. doi: 10.2319/091910-545.1. Epub 2011 Feb 7. PMID: 21299381; PMCID: PMC8923554.
2. Joseph AA, Elbaum J, Cisneros GJ, Eisig SB. A cephalometric comparative study of the soft tissue airway dimensions in persons with hyperdivergent and normodivergent facial patterns. *J Oral Maxillofac Surg.* 1998 Feb;56(2):135-9; discussion 139-40. doi: 10.1016/s0278-2391(98)90850-3. PMID: 9461134.
3. Warren DW, Duany LF, Fischer ND. Nasal pathway resistance in normal and cleft lip and palate subjects. *Cleft Palate J.* 1969 Apr;6:134-40. PMID: 5253575.
4. Warren DW, Hairfield WM, Dalston ET, Sidman JD, Pillsbury HC. Effects of cleft lip and palate on the nasal airway in children. *Arch Otolaryngol Head Neck Surg.* 1988 Sep;114(9):987-92. doi: 10.1001/archotol.1988.01860210053014. PMID: 3408580.
5. Wolford LM. Effects of orthognathic surgery on nasal form and function in the cleft patient. *Cleft Palate Craniofac J.* 1992 Nov;29(6):546-55. doi: 10.1597/1545-1569\_1992\_029\_0546\_eooson\_2.3.co\_2. PMID: 1450196.
6. Bell WH, Fonseca RJ, Kennek JW, Levy BM. Bone healing and revascularization after total maxillary osteotomy. *J Oral Surg.* 1975 Apr;33(4):253-60. PMID: 1054396.
7. Trindade IE, Castilho RL, Sampaio-Teixeira AC, Trindade-Suedam IK, Silva-Filho OG. Effects of orthopedic rapid maxillary expansion on internal nasal dimensions in children with cleft lip and palate assessed by acoustic rhinometry. *J Craniofac Surg.* 2010 Mar;21(2):306-11. doi: 10.1097/SCS.0b013e3181cf5f5f. PMID: 20186095.
8. Imamura N, Ono T, Hiyama S, Ishiwata Y, Kuroda T. Comparison of the sizes of adenoidal tissues and upper airways of subjects with and without cleft lip and palate. *Am J Orthod Dentofacial Orthop.* 2002 Aug;122(2):189-94; discussion 194-5. doi: 10.1067/mod.2002.125234. PMID: 12165773.
9. McNamara JA. Influence of respiratory pattern on craniofacial growth. *Angle Orthod.* 1981 Oct;51(4):269-300. doi: 10.1043/0003-3219(1981)051<0269:IO RPOC>2.0.CO;2. PMID: 6947703.
10. Bushey RS. Adenoid obstruction of the nasopharynx: Naso-Respiratory Function and Craniofacial Growth.: university of Michigan Press, Ann Arbor, MI 1979; 199-232.
11. Candido MS, Monnazzi MS, Gabrielli MAC, Spin-Neto R, Gabrielli MFR, Pereira-Filho VA. Pharyngeal airway space cephalometric evaluation in transverse maxillary deficient patients after SARME. *Brazilian Journal of Oral Sciences.* 2014; 13(4): 288–291.
12. Major MP, Flores-Mir C, Major PW. Assessment of lateral cephalometric diagnosis of adenoid hypertrophy and posterior upper airway obstruction: a systematic review. *Am J Orthod Dentofacial Orthop.* 2006 Dec;130(6):700-8. doi: 10.1016/j.ajodo.2005.05.050. PMID: 17169731.
13. Schulhof RJ. Consideration of airway in orthodontics. *J Clin Orthod.* 1978 Jun;12(6):440-4. PMID: 288741.
14. Sullivan CE, Issa FG, Berthon-Jones M, Eves L. Reversal of obstructive sleep apnoea by continuous positive airway pressure applied through the nares. *Lancet.* 1981 Apr 18;1(8225):862-5. doi: 10.1016/s0140-6736(81)92140-1. PMID: 6112294.
15. Warren DW, Duany LF, Fischer ND. Nasal pathway resistance in normal and cleft lip and palate subjects. *Cleft Palate J.* 1969 Apr;6:134-40. PMID: 5253575.
16. Farzal Z, Walsh J, Lopes de Rezende Barbosa G, Zdanski CJ, Davis SD, Superfine R, Pimenta LA, Kimbell JS, Drake AF. Volumetric nasal cavity analysis in children with unilateral and bilateral cleft lip and palate. *Laryngoscope.* 2016 Jun;126(6):1475-80. doi: 10.1002/lary.25543. Epub 2015 Aug 12. PMID: 26267849; PMCID: PMC4752420.
17. Banabilh SM. Orthodontic view in the diagnoses of obstructive sleep apnea. *J Orthod Sci.* 2017 Jul-Sep;6(3):81-85. doi: 10.4103/jos.JOS\_135\_16. PMID: 28717631; PMCID: PMC5508407.
18. Patel P, Nagarag K, Jain A, Doshi D, Ringane A. Assessment of cephalometric changes in pharyngeal airway involving first premolar extractions in Class II Division 1 Patients and Class I bimaxillary protrusion patients treated with fixed mechanotherapy: A retrospective study. *IJODR.* 2017; 3(1):31-36.
19. Rama AN, Tekwani SH, Kushida CA. Sites of obstruction in obstructive sleep apnea. *Chest.* 2002 Oct;122(4):1139-47. doi: 10.1378/chest.122.4.1139. PMID: 12377834.
20. Ellis H. Gray's anatomy. 37th, Williams R. Warwick, M, Dyson, Bannister LH. 305x235mm. 1598. Illustrated. 1989. Edinburgh: Churchill Livingstone.
21. Aboudara C, Nielsen I, Huang JC, Maki K, Miller AJ, Hatcher D. Comparison of airway space with conventional lateral headfilms and 3-dimensional reconstruction from cone-beam computed tomography. *Am J Orthod Dentofacial Orthop.* 2009 Apr;135(4):468-79. doi: 10.1016/j.ajodo.2007.04.043. PMID: 19361733.
22. Mochida M, Ono T, Saito K, Tsuiki S, Ohyama K. Effects of maxillary distraction osteogenesis on the upper-airway size and nasal resistance in subjects with cleft lip and palate. *Orthod Craniofac Res.* 2004 Nov;7(4):189-97. doi: 10.1111/j.1601-6343.2004.00300.x. PMID: 15562581.



23. Heliövaara A, Ranta R, Hukki J, Haapanen ML. Cephalometric pharyngeal changes after Le Fort I osteotomy in patients with unilateral cleft lip and palate. *Acta Odontol Scand.* 2002 Jun;60(3):141-5. doi: 10.1080/000163502753740142. PMID: 12166906.
24. Mordente CM, Palomo JM, Horta MC, Souki BQ, Oliveira DD, Andrade I Jr. Upper airway assessment using four different maxillary expanders in cleft patients: A cone-beam computed tomography study. *Angle Orthod.* 2016 Jul;86(4):617-24. doi: 10.2319/032015-174.1. Epub 2015 Nov 23. PMID: 26595658; PMCID: PMC8601491.
25. Aras I, Olmez S, Dogan S. Comparative evaluation of nasopharyngeal airways of unilateral cleft lip and palate patients using three-dimensional and two-dimensional methods. *Cleft Palate Craniofac J.* 2012 Nov;49(6):e75-81. doi: 10.1597/12-004. Epub 2012 May 6. PMID: 22558918.
26. Wen-Ching Ko E, Figueroa AA, Polley JW. Soft tissue profile changes after maxillary advancement with distraction osteogenesis by use of a rigid external distraction device: a 1-year follow-up. *J Oral Maxillofac Surg.* 2000 Sep;58(9):959-69; discussion 969-70. doi: 10.1053/joms.2000.8735. PMID: 10981975.
27. Khamashta-Ledezma L, Naini FB. Prospective assessment of maxillary advancement effects: maxillary incisor exposure, and upper lip and nasal changes. *Am J Orthod Dentofacial Orthop.* 2015 Apr;147(4):454-64. doi: 10.1016/j.ajodo.2014.11.028. PMID: 25836005.
28. Muto T, Yamazaki A, Takeda S, Sato Y. Effect of bilateral sagittal split ramus osteotomy setback on the soft palate and pharyngeal airway space. *Int J Oral Maxillofac Surg.* 2008 May;37(5):419-23. doi: 10.1016/j.ijom.2007.12.012. Epub 2008 Mar 10. PMID: 18329854.
29. Hiyama S, Suda N, Ishii-Suzuki M, Tsuike S, Ogawa M, Suzuki S, Kuroda T. Effects of maxillary protraction on craniofacial structures and upper-airway dimension. *Angle Orthod.* 2002 Feb;72(1):43-7. doi: 10.1043/0003-3219(2002)072<0043:EOMPOC>2.0.CO;2. PMID: 11843272.
30. Iwasaki T, Saitoh I, Takemoto Y, Inada E, Kanomi R, Hayasaki H, Yamasaki Y. Improvement of nasal airway ventilation after rapid maxillary expansion evaluated with computational fluid dynamics. *Am J Orthod Dentofacial Orthop.* 2012 Mar;141(3):269-278. doi: 10.1016/j.ajodo.2011.08.025. PMID: 22381487.
31. Oktay H, Ulukaya E. Maxillary protraction appliance effect on the size of the upper airway passage. *Angle Orthod.* 2008 Mar;78(2):209-14. doi: 10.2319/122806-535.1. PMID: 18251620.
32. Niskanen I, Kurimo J, Järnstedt J, Himanen SL, Helminen M, Peltomäki T. Effect of Maxillomandibular Advancement Surgery on Pharyngeal Airway Volume and Polysomnography Data in Obstructive Sleep Apnea Patients. *J Oral Maxillofac Surg.* 2019 Aug;77(8):1695-1702. doi: 10.1016/j.joms.2019.04.001. Epub 2019 Apr 5. PMID: 31047846.
33. Aksu M, Taner T, Sahin-Veske P, Kocadereli I, Konas E, Mavili ME. Pharyngeal airway changes associated with maxillary distraction osteogenesis in adult cleft lip and palate patients. *J Oral Maxillofac Surg.* 2012 Feb;70(2):e133-40. doi: 10.1016/j.joms.2011.10.009. PMID: 22260915.
34. Walker DA, Turvey TA, Warren DW. Alterations in nasal respiration and nasal airway size following superior repositioning of the maxilla. *J Oral Maxillofac Surg.* 1988 Apr;46(4):276-81. doi: 10.1016/0278-2391(88)90009-2. PMID: 3162962.
35. Warren DW, Trier WC, Bevin AG. Effect of restorative procedures on the nasopharyngeal airway in cleft palate. *Cleft Palate J.* 1974 Oct;11:367-73. PMID: 4530749.
36. Kochar GD, Chakranarayan A, Kohli S, Kohli VS, Khanna V, Jayan B, Chopra SS, Verma M. Effect of surgical mandibular advancement on pharyngeal airway dimensions: a three-dimensional computed tomography study. *Int J Oral Maxillofac Surg.* 2016 May;45(5):553-9. doi: 10.1016/j.ijom.2015.10.006. Epub 2015 Dec 11. PMID: 26691933.
37. Yu LF, Pogrel MA, Ajayi M. Pharyngeal airway changes associated with mandibular advancement. *J Oral Maxillofac Surg.* 1994 Jan;52(1):40-3; discussion 44. doi: 10.1016/0278-2391(94)90011-6. PMID: 8263641.

### Discover a bigger Impact and Visibility of your article publication with Peertechz Publications

#### Highlights

- ❖ Signatory publisher of ORCID
- ❖ Signatory Publisher of DORA (San Francisco Declaration on Research Assessment)
- ❖ Articles archived in worlds' renowned service providers such as Portico, CNKI, AGRIS, TDNet, Base (Bielefeld University Library), CrossRef, Scilit, J-Gate etc.
- ❖ Journals indexed in ICMJE, SHERPA/ROMEO, Google Scholar etc.
- ❖ OAI-PMH (Open Archives Initiative Protocol for Metadata Harvesting)
- ❖ Dedicated Editorial Board for every journal
- ❖ Accurate and rapid peer-review process
- ❖ Increased citations of published articles through promotions
- ❖ Reduced timeline for article publication

Submit your articles and experience a new surge in publication services (<https://www.peertechz.com/submission>).

*Peertechz journals wishes everlasting success in your every endeavours.*