

Baku Sakashita¹, Takatsugu Kawase^{1*}, Kazuyoshi Kanai¹, Minako Uchino¹, Tomoko Itazawa¹, Satoshi Nagasaka² and Satsuki Kina²

¹Department of Radiation Oncology, National Center for Global Health and Medicine, Tokyo, Japan

²Department of General Thoracic Surgery, National Center for Global Health and Medicine, Tokyo, Japan

Dates: Received: 02 April, 2014; Accepted: 20 May, 2014; Published: 23 May, 2014

***Corresponding author:** Takatsugu Kawase, Department of Radiation Oncology, National Center for Global Health and Medicine, 1-21-1 Toyama, Shinjuku-ku, Tokyo 162-8655, Japan; Tel: +81-3-3202-7181; Fax: +81-3-3207-1038; Email: tkawase@hosp.ncgm.go.jp

www.peertechz.com

ISSN: 2455-5282

Keywords: Radiotherapy; Intensity-modulated radiotherapy; Volumetric modulated arc therapy; Vertebral metastasis

Case Report

Additional volumetric modulated arc therapy to vertebral metastases abutting the previously irradiated site

Abstract

Introduction: Lung cancer frequently causes metastases to the spine, especially to the thoracic vertebrae, which sometimes compress the spinal cord and induce irreversible palsy. Many patients suffering from metastatic spinal tumors need to undergo repetitive radiotherapy. In such situations, intensity-modulated radiotherapy including volumetric modulated arc therapy can reduce the dose delivered to the spinal cord at the junction.

Case Report: The authors describe a case of thoracic vertebral metastases from lung cancer treated with two courses of radiotherapy. In the second course, volumetric modulated arc therapy was adopted and a columnar-shaped planning target volume with a concave portion was configured.

Conclusion: The authors propose an approach aimed at realizing both junctional safety and the conformality of the spinal column, which may be an option for repetitive irradiation to heterochronic spinal metastases.

Abbreviations

IMRT: Intensity-modulated radiotherapy; VMAT: Volumetric modulated arc therapy; CTV: Clinical target volume; PTV: Planning target volume

Introduction

Lung cancer frequently causes metastases to the spine, especially to the thoracic vertebrae [1], which often cause spinal cord compression and irreversible palsy. Radiotherapy can be useful for reducing the compression. Many patients suffering from metastatic spinal tumors thus need to undergo repetitive radiotherapy. For such patients, performing radiotherapy near a previously irradiated area was problematic in the era of three-dimensional conformal radiotherapy, as leaving a gap between two nearby target volumes is essential to avoid overdosage at the spinal cord. At the same time, leaving a gap could inadvertently allow a substantial volume of metastatic tumor to escape from irradiation. Now that intensity-modulated radiotherapy (IMRT) has been developed, the situation has improved. Using IMRT, radiation oncologists can administer dose gradients to curved target volumes. Furthermore, volumetric modulated arc therapy (VMAT), an IMRT-associated technology, can be used to hollow out an organ at risk.

In this article, we report a case of metastatic spinal vertebral tumor originating from lung cancer. The patient underwent repetitive spinal irradiation. In the treatment course, both of the target volume and the junction were irradiated sufficiently using VMAT technology.

Case Presentation

In April 2008, a 61-year-old female patient with advanced lung

cancer underwent left-upper lobectomy and mediastinal lymph node dissection at the Department of General Thoracic Surgery in our hospital. Pleural dissemination was noted and removed during the surgery. The pathological specimen revealed papillary adenocarcinoma (pT4N2M0), and repeated courses of systemic chemotherapy were subsequently administered.

In December 2012, F-18 2-fluoro-2-deoxy-glucose positron emission tomography/computed tomography (FDG-PET/CT) depicted a bone metastasis in the second thoracic vertebra (Figure 1). Accordingly, the first to the third thoracic vertebrae including the metastatic lesion were irradiated at 40 Gy in 20 fractions with anteroposterior opposing portals (Figure 2).

In June 2013, the patient complained of severe pain in the upper and middle parts of the back. No sensorimotor dysfunction was noted. T1-weighted magnetic resonance images showed a hypointense signal change in the whole fourth thoracic vertebra (Figure 3), which was diagnosed as a vertebral metastasis from the pulmonary adenocarcinoma. The patient was again referred to the Department of Radiation Oncology.

Re-irradiation of the newly metastatic fourth thoracic vertebral tumor adjacent to the formerly irradiated region was taken into account. We decided to utilize VMAT and on-board kilovoltage cone-beam computed tomography imaging to maintain set-up accuracy with a precision of less than 1 to 2 mm, but the possibility of overlapping at the spinal cord was estimated conservatively.

In planning the second radiotherapy course, the clinical target volume (CTV) included not only the fourth but also the fifth vertebra, which had no remarkable metastasis was detected using magnetic

resonance imaging. This is because we intended to irradiate both the affected vertebra and the adjacent vertebral bodies, as is the standard procedure [2]. In contrast, the third vertebra was excluded to avoid overlapping. The volume of the spinal cord was then excluded from the CTV. A planning target volume (PTV) was generated by adding a three-dimensional margin of 2 mm to the CTV. In addition, the

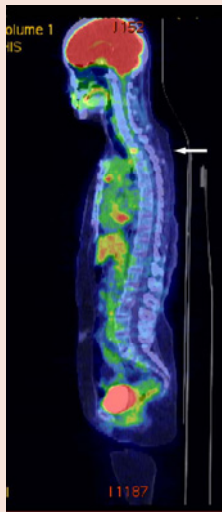


Figure 1: F-18 2-fluoro-2-deoxy-glucose positron emission tomography/computed tomography (FDG-PET/CT) showed a bone metastasis in the second thoracic vertebra (arrow).

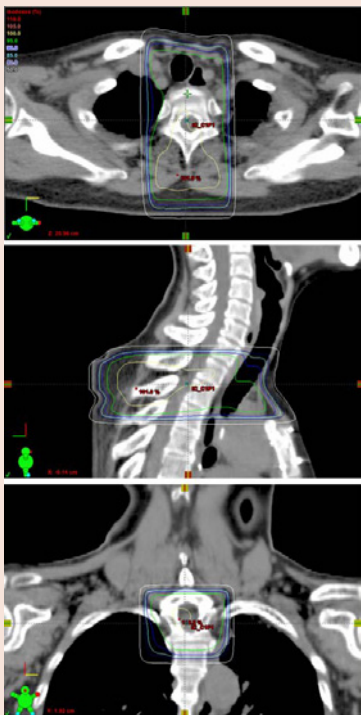


Figure 2: The isodose distributions of the first irradiation to the second thoracic vertebral metastasis.

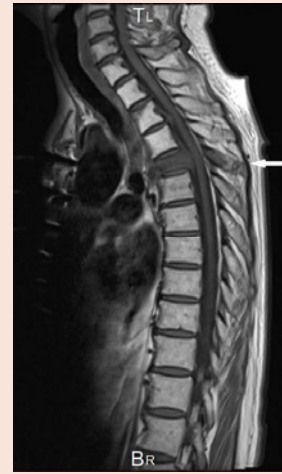

Figure 3: Six months after the first irradiation to the second thoracic vertebra, T1-weighted magnetic resonance images showed a hypointense signal change in the whole fourth thoracic vertebra (arrow).

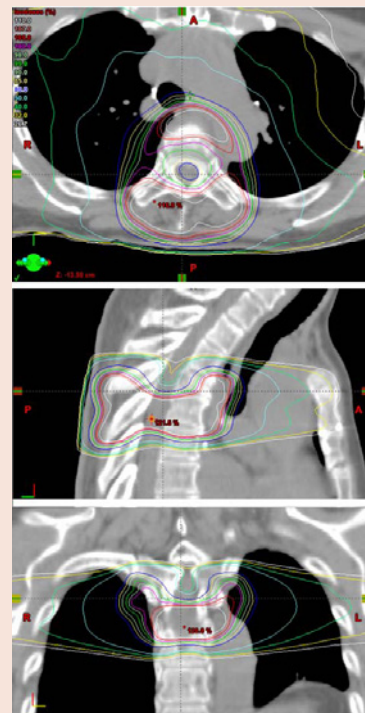

Figure 4: The isodose distributions of the second irradiation to the fourth thoracic vertebral metastasis using volumetric modulated arc therapy.

fourth and fifth vertebrae and spinal cord were each delineated for the plan evaluation. Using these settings, a four-partial-arc, single isocenter 10-MV VMAT plan was planned using the RapidArc technique on the Eclipse radiotherapy planning system (Varian, Palo Alto, California USA). Beams covered from 114° to 246°, using 228° arcs. The goal of optimization for the PTV dose was to have 90% of the PTV covered by 80% of the dose of 37.5 Gy in 15 fractions. The

spinal cord for optimization, limited ± 2 cm in longitudinal length at the junction, was delineated. The maximum dose covering 1% of the partial volume in the spinal cord for reference, D_{max} , was intended to be below 10 Gy.

The patient was treated using a Clinac iX Linear accelerator (Varian, Palo Alto, California USA) with a personalized thermoplastic mask on a Vac-Lok patient fixation device (CIVCO Medical Solutions, Coralville, Iowa USA) in the supine positions. Daily set-up verification was performed using on-board kilovoltage cone beam computed tomography. Each daily irradiation procedure required less than fifteen minutes. The isodose distributions of the second VMAT irradiation are shown (Figure 4). The dose delivered to the spinal cord near the junction was reduced by the “concave” shape of the dose distribution in that area. The fifth vertebra including the vertebral bodies, pedicles, transverse processes, and spinous processes were sufficiently irradiated. The dose-volume histograms of the PTV, the fourth vertebra, the fifth vertebra, the spinal cord, the spinal cord for optimization, the esophagus and the lungs were calculated (Figure 5). The dose-volume parameters are shown in Table 1.

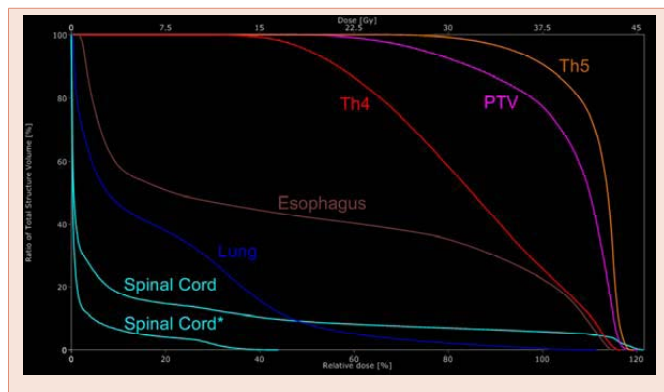


Figure 5: The dose-volume histograms of the planning target volume (PTV), the fourth thoracic vertebra (Th4), fifth thoracic vertebra (Th5), and the organs at risk including spinal cord, lung and esophagus. Spinal Cord* represents the partial volume of the spinal cord for optimization.

Table 1: Dosimetric parameters in the dose-volume histograms.

Structure	Metric	Goal (Gy)	VMAT plan (Gy)
PTV	D_{90}	30.0 (80.0)	31.7 (84.5)
	D_{mean}	-	39.3 (104.8)
Th4	D_{mean}	-	31.5 (84.0)
Th5	D_{mean}	-	41.6 (110.8)
Spinal Cord (for optimization)	D_{max}	10.0	12.2 (32.5)
Spinal Cord	D_{max}	-	45.6 (121.5)
Esophagus	D_{max}	-	43.2 (115.1)
Lung	V_{20}	-	6.9 [†]

VMAT: volumetric modulated arc therapy; PTV: planning target volume; Th4: the fourth thoracic vertebra; Th5: the fifth thoracic vertebra; D_{mean} : the mean dose irradiated to the volume; D_{max} : the maximum dose irradiated to 1% of the structure volume; V_{20} : the percentage of the volume irradiated at and above 20Gy.

*Data in parentheses are percentages to the prescribed dose of 37.5 Gy.

[†]The figure represents the percentage.

Two weeks after the VMAT irradiation, spontaneous pain around the thoracic vertebra was reduced to 0-1 using the Visual Analog Scale. No skin erythema was observed. The patient maintained ambulatory ability without severe local pain and followed a satisfactory posttherapeutic course.

Discussion

Adherence to the dose constraint of the spinal cord is extremely important when repetitive irradiation to metastatic tumors in the spinal vertebrae is attempted. Radiation oncologists have given full consideration to the tolerant dose described by Emami [3] and recently emphasized in the Quantitative Analysis of Normal Tissue Effects in the Clinic (QUANTEC) [4]. Yet this consideration sometimes causes a difficult dilemma when it is necessary to plan repetitive radiotherapy for heterochronic vertebral metastases from malignant tumor. Especially when new metastases have arisen adjacent to the target volume formerly irradiated, a gap volume where sufficient radiation is not delivered can easily though inadvertently be left when three-dimensional irradiation is used without any image-guiding.

IMRT technology including VMAT is believed to be the solution to this dilemma. Attempts to prescribe IMRT for vertebral tumor in order to avoid the spinal cord have already been reported in many precedent articles [5-7]. In these articles, the total volume of the spinal cord penetrating the PTV was excluded from the actual irradiated volume to reduce the spinal dose. This technique may be ideal to prevent violation of the spinal dose constraint and to avoid excessive re-irradiation of the identical vertebra. In the present study, however, we set a “concave” region, an area of reduced isodose, at the junctional surface of the PTV, while the greater part of the spinal cord was included in the volume. Our method was intended to deliver a substantial dose to the area around the spinal cord near the target vertebrae including the pedicles, transverse processes, and spinous processes. This is because these structures are usually deemed to harbor metastatic tumor cells even if no apparent metastatic lesions are visualized by radiographical examinations [8]. Using our method, the junction area around the spinal cord could be well irradiated while the simulated dose delivered to the spinal cord itself near the junction was successfully reduced below the tolerant dose reported. Furthermore, overdosage at the spinal cord due to unexpected interfractional overlapping was assumed in our second radiotherapy plan. Conformity of the target volume and avoidance of the organ at risk may always be a necessary trade-off; therefore our technique in the present case may be one of the viable options for administering VMAT to metastatic spinal tumors.

References

- Rief H, Muley T, Bruckner T, Welzel T, Rieken S, et al. (2014) Survival and prognostic factors in non-small cell lung cancer patients with spinal bone metastases. *Strahlenther Onkol* 190: 59-63.
- Kaasa S, Brenne E, Lund JA, Fayers P, Falkmer U, et al. (2006) Prospective randomised multicenter trial on single fraction radiotherapy (8 Gy×1) versus multiple fractions (3 Gy×10) in the treatment of painful bone metastases. *Radiother Oncol* 79: 278-284.
- Emami B, Lyman J, Brown A, Coia L, Goitein M, et al. (1991) Tolerance of



- normal tissue to therapeutic irradiation. *Int J Radiat Oncol Biol Phys* 21: 190-122.
4. Kirkpatrick JP, van der Kogel AJ, Schultheiss TE (2010) Radiation dose-volume effects in the spinal cord. *Int J Radiat Oncol Biol Phys* 76: S42-S49.
 5. Navarria P, Mancosu P, Alongi F, Pentimali S, Tozzi A, et al. (2012) Vertebral metastases reirradiation with volumetric-modulated arc radiotherapy. *Radiother Oncol* 102: 416-420.
 6. Ryu S, Fang Yin F, Rock J, Zhu J, Chu A, et al. (2003) Image-guided and intensity-modulated radiosurgery for patients with spinal metastasis. *Cancer* 97: 2013-2018.
 7. Milker-Zabel S, Zabel A, Thilmann C, Schlegel W, Wannenmacher M, et al. (2003) Clinical results of retreatment of vertebral bone metastases by stereotactic conformal radiotherapy and intensity-modulated radiotherapy. *Int J Radiat Oncol Biol Phys* 55: 162-167.
 8. Sutcliffe P, Connock M, Shyangdan D, Court R, Kandala NB, et al. (2013) A systematic review of evidence on malignant spinal metastases: natural history and technologies for identifying patients at high risk of vertebral fracture and spinal cord compression. *Health Technol Assess* 17: 1-274.

Copyright: © 2014 Sakashita B, et al. This is an open-access article distributed under the terms of the Creative Commons Attribution License, which permits unrestricted use, distribution, and reproduction in any medium, provided the original author and source are credited.

Citation: Sakashita B, Kawase T, Kanai K, Uchino M, Itazawa T, et al. (2014) Additional volumetric modulated arc therapy to vertebral metastases abutting the previously irradiated site. *Global J Med Clin Case Reports* 1: 001-004. DOI: 10.17352/2455-5282.000001