

Madhusudan Haldar¹, Shyamal Dasgupta¹, Shamim Khandaker^{2*}, Shabana Munshi², Nabojibon Mondal³ and Sudhir Adhikari⁴

¹Assistant Professor, NBMC, Department of O&G, North Bengal Medical College, Sushrutanagar, Darjeeling, India

²RMO cum Clinical tutor, NBMC, Department of O&G, North Bengal Medical College, Sushrutanagar, Darjeeling, India

³PG student, NBMC, Department of O&G, North Bengal Medical College, Sushrutanagar, Darjeeling, India

⁴Professor and Head of Department of Obst & Gyn, NBMC, Department of O&G, North Bengal Medical College, Sushrutanagar, Darjeeling, India

Dates: Received: 23 July, 2014; Accepted: 12 August, 2014; Published: 14 August, 2014

***Corresponding author:** Shamim Khandaker, RMO cum Clinical tutor, NBMC, Department of O&G, North Bengal Medical College, Sushrutanagar, Darjeeling, India, E-mail: shamim_khandaker@yahoo.co.in

www.peertechz.com

ISSN: 2455-5282

Keywords: Uterus didelphys; Obstructed hemivagina; Vaginal septum excision; Ultrasound; MRI

Introduction

The prevalence of congenital Mullerian duct anomalies is 1% [1]. The syndrome of obstructed hemivagina and ipsilateral renal anomaly (OHVIRA) is a rare congenital anomaly of the Mullerian ducts (paramesonephric) and Wolffian structures (mesonephric). It usually includes unilateral renal anomalies and uterine didelphys [2]. The triad is initially reported in 1950. Most of the women suffering from OHVIRA syndrome are diagnosed late due to the rare incidence and the non specific clinical presentation. Moreover, the menstrual flow that comes from the patent unobstructed hemivagina gives the appearance of normal menses. Consequently accurate diagnosis and surgical treatment can be delayed for several months or even years. We present a case report of a patient with the triad of uterus didelphys, obstructed hemivagina and ipsilateral renal agenesis managed presenting late with symptoms of recurrent pyocolpos following dilatation and evacuation for midtrimester miscarriage.

Case Presentation

An 18 years old, Indian, female who was married since 3 years presented with profuse foul smelling discharge per vagina along with cyclical dysmenorrhoea. She has a history of spontaneous miscarriage at 16 weeks of gestation 2 years earlier for which she has undergone dilatation and evacuation of the uterine cavity. Her symptom of profuse foul smelling vaginal discharge starts 2-3 weeks after the surgical intervention for which she seek medical advice and treated with antibiotics. Despite several antibiotic courses her symptom became recurrent and debilitating; causing poor quality of life. She was ultimately referred to our unit in a tertiary care hospital. Her

Case Report

An Unusual Case of Recurrent Pyocolpos Following Midtrimester Miscarriage Revealed as Obstructed Hemivagina with Ipsilateral Renal Agenesis (OHVIRA) Syndrome

Abstract

Obstructed hemivagina with ipsilateral renal agenesis (OHVIRA Syndrome) is a rare congenital anomaly. It mostly presents with severe dysmenorrhea and a palpable mass due to unilateral hematocolpos. Sometime it presents in unusual way with prolonged vaginal bleeding and profuse vaginal discharge. We report a case of an 18-year-old married female with OHVIRA syndrome presenting late with symptoms of recurrent pyocolpos following dilatation and evacuation for midtrimester miscarriage that was diagnosed on the basis of MRI and managed by vaginal septotomy.

menarche was at 12 years of age with regular cycle and duration of 4-5 days but blood mixed discharge continued for another 5-6 days; for which she did not consulted at that time. She had also given history of cyclical dysmenorrhoea but not debilitating and treated with NSAIDS.

On per vaginal examination, no hymen was found; a 2x3 cm bulge was felt in the right vaginal wall with presence of one cervix deviated more towards left side. Transvaginal ultrasonography showed evidence of bicornuate bicollis uterus with right sided mild endocervical collection. MRI of lower abdomen and pelvis was advised for better clinical correlation. MRI report (plain study) revealed there were two separate uterine cavity (right uterus measures 55x28x25 mm and left uterus measures 60x31x25 mm) and medial surface of the two separate uterus partially fused with two separate cervix. Two separate vagina was seen and right vagina was filled up with fluid, blood products (hematocolpos) with air (? infected). There was also single left kidney of normal size, shape and signal intensity with no hydronephrosis and hydroureter. Intravenous pyelogram confirmed that there was no right kidney and presence of left kidney with normal excretory function. The diagnosis of obstructed hemivagina with ipsilateral renal agenesis (OHVIRA) syndrome was made. She was taken up for operation after proper preoperative evaluation; where the right sided vaginal bulge was incised. On incision foul smelling pus came out which was sent for culture and sensitivity. On exploration of the incised vaginal septum a cervix was found on the right side. Vaginal septum was excised till the junction of both cervixes with haemostasis of the septum margin. Postoperatively she was given broad spectrum antibiotics with uneventful post operative period.

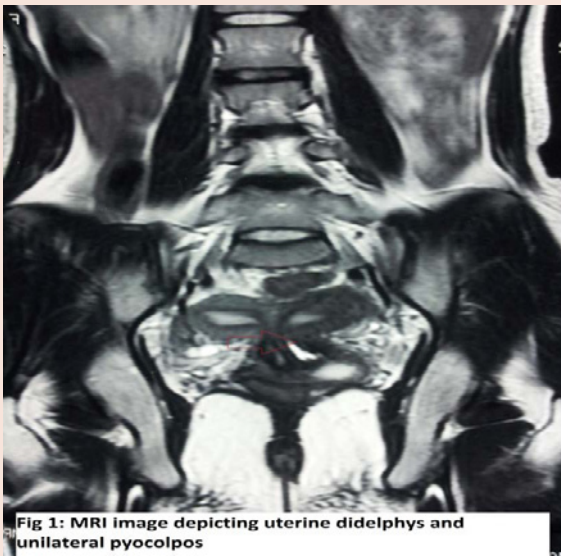


Fig 1: MRI image depicting uterine didelphys and unilateral pyocolpos

Figure 1: MRI image depicting uterine didelphys and unilateral pyocolpos.

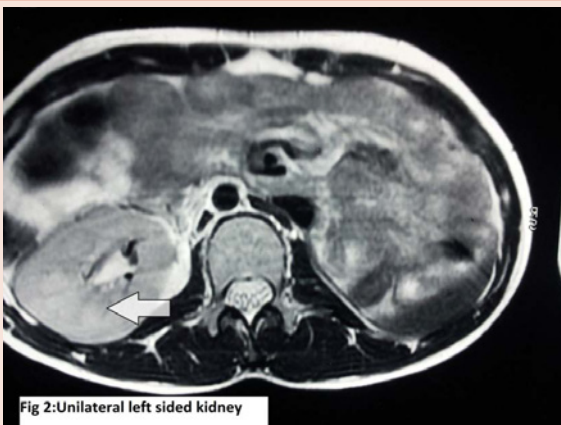

Fig 2: Unilateral left sided kidney

Figure 2: Unilateral left sided kidney.

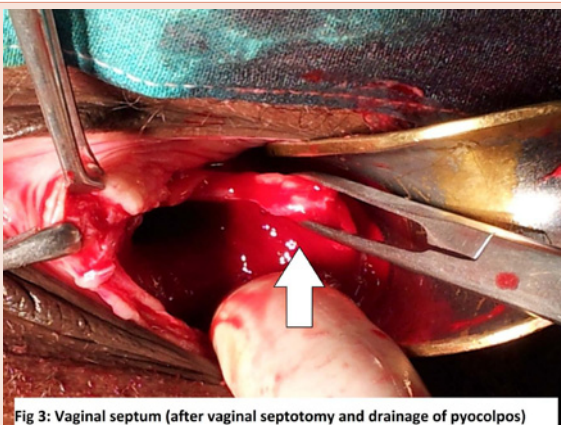


Fig 3: Vaginal septum (after vaginal septotomy and drainage of pyocolpos)

Figure 3: Vaginal septum (after vaginal septotomy and drainage of pyocolpos).

Discussion

The exact aetiology and pathogenesis of OHVIRA syndrome is still unknown. Vaginal development requires the fusion of the mesodermal Müllerian ducts and the endodermal urogenital sinus (UGS). The caudal tip of the utero-vaginal protrusion (UVP) inserts into the dorsal wall of the UGS forming the Müllerian or sinus tubercle. The sinus tubercle induces the formation of paired endodermal evaginations- the sinovaginal bulbs. Sinovaginal bulb is a solid core extending from UGS to caudal portion of UVP; which completes canalization at 20 weeks [3]. Mijsberg [4] identified the sinovaginal bulbs as “Wolffian bulbs” and suggested they are derivatives of the caudal aspects of the Wolffian (mesonephric) and paramesonephric (Müllerian) ducts. Acien concluded that the histopathologic findings, suggested a role for the Wolffian ducts in vaginal formation [5]. According to this theory; absence of the opening of caudal portion of one of the Wolffian ducts into the urogenital sinus along with absence of the urethral bud sprouting is the cause of unilateral renal agenesis associated with imperforate hemivagina. The “inductor” function of the Wolffian duct on the Müllerian duct is also failing and there is usually utero-vaginal duplicity associated with blind hemivagina with the ipsilateral renal agenesis [5]. On the side where the Wolffian duct is absent the Müllerian duct is displaced laterally so it cannot fuse with the contralateral duct, resulting in didelphic uterus, and cannot come into contact with the urogenital sinus centrally [5].

OHVIRA syndrome is rare and lack of awareness of this syndrome frequently leads to delayed diagnosis or misdiagnosis. The classical presentation is that of a young girl presenting with severe cyclical dysmenorrhea, after attaining menarche. Usually they are treated symptomatically until they develop an abdominal mass and pressure symptoms. Pelvic pain is the most common presenting symptom (90%) followed by an abdominal mass (40%) and pressure symptoms [6]. Infrequently longitudinal vaginal septa will be found to be only partially obstructing and a small opening in the septum can be found during menses with close inspection. These patient presents with irregular and prolonged bleeding to profuse vaginal discharge; as in our patient. Occasionally, the pinpoint opening provides a pathway for organisms to access the obstructed vagina leading to pelvic infection and pyocolpos [7]. Sometime they can also present at a later age with foul smelling vaginal discharge due to pyocolpos [8]. Physical examination is unlikely to reveal a tense bulge, but a slight fullness may sometimes be appreciated in the paravaginal area.

Along with dilated hemivagina (haematocolpos), a dilated uterine cavity (haematometros) and fallopian tube (haematosalpinx) may occur. Sometime haemoperitoneum can also noted as a consequence of blood stasis and retrograde menstruation and ultimately leads to endometriosis with its implication on future fertility [9,10]. Ultrasonography especially transvaginal (TVS) can make the diagnosis as it is readily available, quick, economic and without radiation exposure [10]. Three-dimensional (3D) ultrasound has the potential of becoming the imaging standard. However, MRI is currently considered the best imaging modality [11].

Surgical excision of the septum and drainage of the obstructed vagina is the definitive treatment [12]. Early recognition along with obstructing vaginal septum resection is necessary for prevention of complications related to chronic cryptomenorrhoea, such as endometriosis, pelvic adhesions, and infectious collections (pyocolpos, pyometros and pyosalpinx) along with preservation of fertility [12].

References

1. Ashton D, Amin HK, Richart RM, Neuwirth RS (1988) The incidence of asymptomatic uterine anomalies in women undergoing transcervical tubal sterilization. *Obstet Gynecol* 72: 28-30.
2. Kimble RM, Khoo SK, Baartz D, Kimble RM (2009) The obstructed hemivagina, ipsilateral renal anomaly, uterus didelphys triad. *Aust NZ J Obstet Gynaecol* 49: 554-557.
3. Moore KL, Persaud TVN (2003) The urogenital system: the developmental of the genital system. In: *The developing human: clinically oriented embryology*, 7th edn. WB Saunders, Philadelphia.
4. Mijsberg WA (1924) Uber die entwicklung der vagina, des hymen und des sinus urogenitalis beim menschen. *Z Anat Entwicklungsgesch* 74: 684-760.
5. Acien P (1992) Embryological observations on the female genital tract. *Hum Reprod* 7: 437-445.
6. Christianson MS, Yates MM, Woo I, Khafagy A, Garcia JE, et al. (2012) Obstructed hemivagina and ipsilateral renal anomaly (OHVIRA): diagnostic features and management of a frequently misdiagnosed syndrome. *Fertil Steril* 98: S222.
7. Marjan Attaran. Surgical techniques for management of anomalies of the Mullerian ducts. In: Tommaso Falcone, William W. Hurd, editors. *Clinical reproductive medicine and surgery: a practical guide*. 2nd edition. New York: Springer Science+Business Media; 2013.
8. Dhar H, Yasser AR, Illham H (2011) Uterus didelphys with obstructed hemivagina, ipsilateral renal agenesis and right pyocolpos: A case report. *Oman Med J* 26: 447-450.
9. Troiano RN, McCarthy SM (2004) Mullerian duct anomalies: imaging and clinical issues. State of the art. *Radiology* 233:19-34.
10. Stassart JP, Nagel TC, Prem KA, Phipps WR (1992) Uterus didelphys, obstructed hemivagina, and ipsilateral renal agenesis: the University of Minnesota experience. *Fertil Steril* 57: 756-761.
11. Scarsbrook AF, Moore NR (2003) MRI appearance of Mullerian duct abnormalities. *Clin Radiol* 58: 747-754.
12. Gholoum S, Puligandla PS, Hui T, et al. (2006) Management and outcome of patients with combined vaginal septum, bifid uterus and ipsilateral renal agenesis (Herlyn-Werner-Wunderlich syndrome). *J Pediatr Surg* 41: 987-992.

Copyright: ©2014 Haldar M, et al. This is an open-access article distributed under the terms of the Creative Commons Attribution License, which permits unrestricted use, distribution, and reproduction in any medium, provided the original author and source are credited.

Citation: Haldar M, Dasgupta S, Khandaker S, Munshi S, Mondal N, et al. (2014) An Unusual Case of Recurrent Pyocolpos Following Midtrimester Miscarriage Revealed as Obstructed Hemivagina with Ipsilateral Renal Agenesis (OHVIRA) Syndrome. *Global J Med Clin Case Reports* 1(1): 021-023. DOI: 10.17352/2455-5282.000006