



J Passini Sánchez^{1*}, FJ Pérez Lara², R Marín Moya² and H Oliva Muñoz³

¹Traumatology resident, Hospital de Antequera, Málaga, Spain

²Digestive Surgeon, Service of Surgery, Hospital de Antequera, Málaga, Spain

³Chief of Surgery Service, Hospital de Antequera, Málaga, Spain

Dates: Received: 02 June, 2017; **Accepted:** 19 June, 2017; **Published:** 20 June, 2017

***Corresponding author:** Julieta Passini Sanchez, Traumatology resident, Hospital de Antequera, Málaga, Spain, Tel: 600766326; E-mail: julietapassini@gmail.com; javinewyork@hotmail.com

Keywords: Lower member amputation; Arthroplasty; Knee; Hip

<https://www.peertechz.com>

Case report

Lower Member Amputation in Patient with Total Hip or Knee Arthroplasty

Abstract

In recent years the incidence of both amputations as total joint replacement surgery of lower limbs has been increased. So it is not rare to find both circumstances in the same patient. We discuss about the technical problem of this eventuality.

Case

The increase in joint replacement surgery is due to the aging of the population, the expansion of the indication criterias and the greater expectation and demand of patients. In the US, more than one million of total atroplasties per year are performed, being the main cause osteoarthritis [1]. The joint is replaced by prosthetic components that are fixed to the bone directly or by means of bone cement [2]. Total hip arthroplasty (THA) employs an acetabular component, a femoral or stem component, and the femoral head [3]. While total knee arthroplasty (TKA) requires a femoral component, a tibial component and a patellar component. Models, materials, sizes and types of fixation vary according to the characteristics of the patient [4].

On the other hand, amputation of lower limbs has also increased due to the increase of life expectancy. The most frequent cause in developed countries is vascular disease (80-90%) and it affects most commonly men between 50-75 years. It is mainly associated with atherosclerosis and diabetes [5].

Thus, it is not uncommon to find patients with prostheses that require amputation. In order to calculate the level of section and to propose the intervention, it is necessary to take into account the location of the prosthesis and the height of the stem.

We recently had two cases in our hospital, one with a primary TKA (Figure 1A) and another with a THA review

(Figure 1B), who underwent supracondylar amputation due to irreversible vascular ischemia. In the patient with TKA, the procedure happened without complications. However, in the patient with THA, a second intervention was required because the height of the femoral stem was not taken into account when the bone section was performed (Figure 2A). In a second time, with the appropriate instruments (Stryker® diamond bone saw) a femoral stem section was performed 6-7 cm from the tip (Figure 2B).

Therefore, we believe that the personal history of a hip or knee prosthesis is an important detail when planning a lower limb amputation, requiring a thorough radiological control (preoperative and intraoperative measurements) and adequate staff and Instruments. In the case of TKA, fewer doubts arise because a more proximal amputation can be performed if necessary. The problem lies in patients with THA, in which, if the appropriate section height is not calibrated, we can find the disadvantage of the femoral stem. Requiring a second intervention and special instruments with the consequent risks and costs entailed.

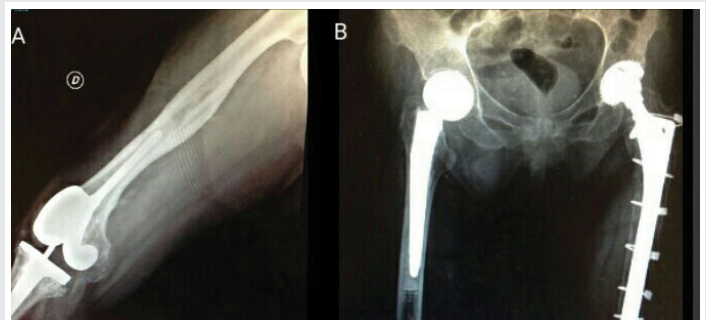

Figure 1: (A) Right lateral knee radiograph in a patient with PTR. (B) Anteroposterior radiograph of the pelvis and proximal femur. It is observed in primary PTC right hip and PTC left hip revision with cerclages.

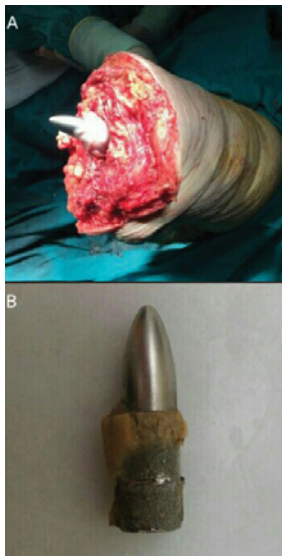


Figure 2: (A) Intraoperative image after supracondylar amputation in the patient with PTC. Note the height of the femoral stem relative to the cut zone. (B) Portion of the femoral stem of the PTC, after section in a second time with the Stryker® diamond saw.

References

1. Maradit Kremers H, Larson DR, Crowson CS, Kremers WK, Washington RE, et al. (2015) Prevalence of Total Hip and Knee Replacement in the United States. *J Bone Joint Surg Am* 97: 1386-1397. [Link: https://goo.gl/3jmu9m](https://goo.gl/3jmu9m)
2. Campbell WC, Canale ST, Beaty JH (2013) *Campbell's Operative Orthopaedics*. Philadelphia, PA, Elsevier. [Link: https://goo.gl/THGgAi](https://goo.gl/THGgAi)
3. Bozic KJ, Kurtz SM, Lau E, Ong K, Vail TP, et al. (2009) The epidemiology of revision total hip arthroplasty in the United States. *J Bone Joint Surg Am* 91: 128-133. [Link: https://goo.gl/eQR7RK](https://goo.gl/eQR7RK)
4. Hirschmann MT, Becker R (Ed) (2015) *The Unhappy Total Knee Replacement: A Comprehensive Review and Management Guide*. Springer. [Link: https://goo.gl/9mwW1N](https://goo.gl/9mwW1N)
5. Dziadosz DR, Bergmann KA (2014) *Lower Extremity Amputations*. Orthopaedic Knowledge Update 11 (Ed). 659-671. [Link: https://goo.gl/pqvPfm](https://goo.gl/pqvPfm)