



Mathi M, Arun A, Nelson R, Andre Das and Umbaran G*

Surgical Department, Kajang Hospital, Selangor, Malaysia

Dates: Received: 07 June, 2017; Accepted: 22 June, 2017; Published: 23 June, 2017

*Corresponding author: Umbaran G, Faculty of Medicine, Cyberjaya University College of Medical Sciences (CUCMS), Cyberjaya, Selangor, Malaysia, E-mail: umbaran78@yahoo.co.uk

<https://www.peertechz.com>

Case Report

Anal Eroticism with plastic bottle ways of management: A Case Report

Abstract

Foreign bodies in the rectum often pose a challenging diagnostic and management dilemma that begins with the initial evaluation in the emergency department and continues through the post extraction period. Because of the wide variety of objects and the variation in trauma caused to local tissues of the rectum and distal colon, a systematic approach to the diagnosis and management of rectal foreign bodies is essential. We present a case of 34 year old gentleman presented to emergency department with complaint of constipation for 2 days and claims he had inserted a plastic bottle in his anus 2days ago and unable to remove it. After failure of extraction of the bottle trans-anally and endoscopically, a mini laparotomy and incision on the sigmoid colon done to remove the foreign body. Patient was referred to the psychiatrist for his perversion disorder, which was also mandatory for preventing recurrences.

Introduction

Rectal foreign bodies often pose a challenging diagnostic and management dilemma that begins with the initial evaluation in the emergency department and continues through the post extraction period. Objects can be inserted in to the rectum for diagnostic or therapeutic purposes, self-treatment of anorectal disease during criminal assault or accidents, or (most commonly) for sexual purposes. Numerous objects, various fruits and vegetables, nails, light bulbs, bottle, and spray cans, have been described as retained rectal foreign bodies. Because of the wide variety of objects and the variation in trauma caused to local tissues of the rectum and distal colon, a systematic approach to the diagnosis and management of rectal foreign bodies is essential. One of the most common problems encountered in the management of rectal foreign bodies is the delay in presentation, as many patients are embarrassed and reluctant to seek medical care. Most of these patients present to the emergency department after efforts to remove the object at home. Moreover, in the emergency, patients may often be less than truthful regarding the reason for their visit, leading to extensive workups and further delays. Nevertheless after extraction, delayed perforation or significant bleeding from the rectum may occur.

Case Report

A 34 year old gentleman presented to emergency department with complaint of constipation for 2 days and claims he inserted a plastic bottle in his anus 2days ago and unable to remove it. He was unable to describe the size and nature of the bottle because he was under drug influence at

that moment. He was still able to pass minimal flatus, had minimal blood per rectally while trying to remove the bottle. However he denied any abdominal pain or vomiting. On further history, he has high risk behaviors such as drug ingestions and history of imprisonment before.

On examination, he had mild lower abdominal tenderness but no guarding. On per rectal examination the tip of the bottle can be felt. Other systemic examination was unremarkable. Vital signs were stable. He had no fever and no tachycardia. Blood investigation showed elevated white cell count but there was no metabolic acidosis. We were unable to visualize any foreign body on pelvic x rays.

We performed examination under anesthesia for removal of foreign body trans-anally. While doing the procedure we encountered difficulty to remove the foreign body due to size and position of the bottle at recto sigmoid junction, thus decision was made to perform a laparotomy. Lower midline laparotomy was performed. A small incision was made over sigmoid colon and the foreign body was removed. A primary anastomosis was subsequently done. In view of the traumatic rectal injury while removing the bottle transanally, a covering ileostomy was created. Patient had undergone reversal of ileostomy 2 months after the initial laparotomy. He was followed up in the clinic and recovered well from both surgeries (Figures 1-5).

Discussion

Colorectal foreign bodies are not an uncommon presentation to the emergency or colorectal surgical department [1,2]. Men

between 30's and 40's are more commonly associated with foreign body in rectum such as this patient. According to few literatures a useful classification of rectal foreign bodies has been to categorize them as voluntary versus involuntary and sexual versus nonsexual [2].

One of the most common categories of rectal foreign bodies is objects that are inserted voluntarily and for sexual stimulation [2,3]. We suspect that this patient also did it for the same purpose. The foreign bodies commonly reported were plastic or glass bottles, cucumbers, carrots, wooden, or rubber objects [4]. Involuntary sexual foreign bodies are almost exclusively in the domain of rape and sexual assault. Even

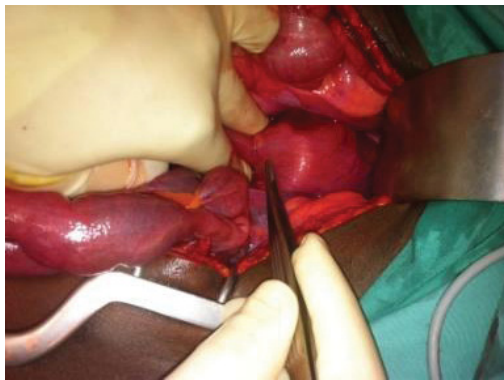


Figure 1: Foreign body can be seen at rectosigmoid junction.

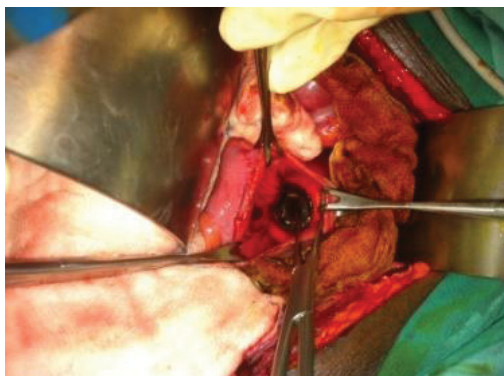


Figure 2: Colotomy was performed.

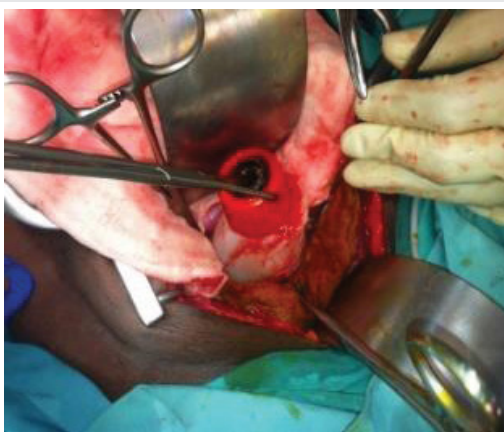

Figure 3: Removing the foreign body.

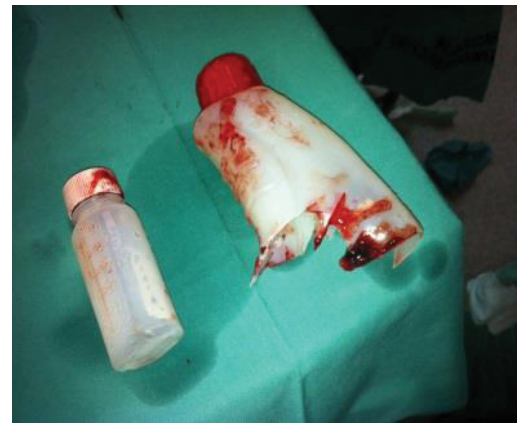

Figure 4: Completely removed foreign body.

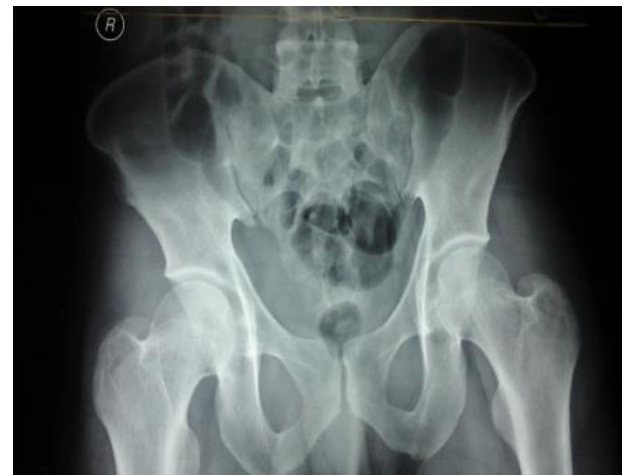

Figure 5: Pelvic x-ray of patient.

with routine transanal extraction, experts recommends several hours of close observation with serial abdominal examinations and plain films as indicated [4,5]. Bleeding from lacerations in the rectal mucosa is generally self-limited. Death from sepsis and multisystem organ failure has been reported. Traumatic disruption of the anal sphincter can result in mild to severe fecal incontinence, depending on the degree of the injury. Attempts for surgical correction of any sphincter injury should be delayed until adequate time has passed to evaluate any resultant defect and clinical symptoms. Therefore, all retained rectal foreign bodies should be treated as potentially hazardous [4-7]. They may complain of vague abdominal pain, rectal bleeding or pain and sometimes constipation. Signs of infection or perforation may be evident in complicated cases [2,5]. Physical examination should include a careful abdominal examination to assess for signs of peritonitis or the ability to palpate an object trans-abdominally. Rectal examination is essential in the diagnosis, but it should be performed after X-ray abdomen to prevent accidental injury to the surgeon from sharp objects. The foreign body may be palpable in the distal rectum. Bright red blood per rectum is often seen but is not always present. Careful attention should also be paid to the status of the sphincter, especially in patients without a prior history of foreign body placement and in those non-voluntary cases [4,7]. In patients without sphincter injury, the rectal

sphincter may have increased tone secondary to muscular spasm as a result of the foreign object. The sphincter may have obvious damage with visible injury to both the internal and external sphincter and should be carefully examined [2,7]. Laboratory evaluation is not very helpful in the patient with a rectal foreign body. If the patient has a suspected perforation, the white blood cell count may be elevated and acidosis may be present on chemistry. These laboratory tests are not very helpful, as the physical examination will be more revealing as to the extent of injury. Laboratory tests should be limited to those that are necessary in case an operation is needed. Radiologic evaluation is far more important than any laboratory test [4,7]. Routine x-rays of the abdomen and pelvis should be obtained to further delineate the foreign body position and determine shape, size, and presence of pneumoperitoneum. The first step in the evaluation and management of a patient with a rectal foreign body is to determine whether or not a perforation occurred [7]. When a perforation is suspected, it should be determined as soon as possible whether the patient is stable or unstable. Hypotension, tachycardia, severe abdominopelvic pain, and fevers are indicative of a perforation. If there is free air or obvious peritonitis indicating a perforation, then the patient needs immediate resuscitation with intravenous fluids and broad-spectrum antibiotics. A Foley catheter and nasogastric tube should be placed, and appropriate blood samples should be sent to the laboratory. If the patient appears stable and has normal vital signs and a perforation is suspected, a computed tomographic (CT) scan often helps determine if there has been a rectal perforation [4,7]. When a foreign body is removed or absent in the rectal vault, rigid proctoscopy or endoscopic evaluation may reveal the rectal injury or the foreign body located higher in the recto sigmoid [4]. In clinically stable patients without evidence of perforation or peritonitis, the rectal foreign body should be removed either in the emergency department or in the operating room, if general anesthesia is needed [6,7]. Depending on the size and shape of the object various methods have been described. Most objects can be removed transanally, and if not, then a transabdominal approach is used [7]. In this patient due to difficulty in removing the foreign body transanally we proceeded with laparotomy. Many authors recommend direct visualization with rigid proctoscopy or flexible sigmoidoscopy for all patients after the object has been removed to evaluate the status of the rectum and rule out ischemia or wall perforation [7,8]. When attempting to remove a rectal foreign body transanally, the most important factor in successful extraction is patient relaxation [5,8]. This can be achieved with a perianal nerve block, a spinal anesthetic, or either of these in combination with intravenous conscious sedation. After the patient has been appropriately sedated and anesthetized attempts should be made to remove the object. The high lithotomy position in candy cane stirrups facilitates removal of most objects and has the added benefit of allowing for downward abdominal pressure to aid in extraction of the foreign body. The anal canal should then be gently dilated to 3 fingers' breadth. If the foreign body can be easily palpated, it is amenable to transanal extraction using one of many clamps and instruments [9]. After successful removal of a rectal foreign

body, the mucosa of the colon and rectum needs to be examined. A rigid sigmoidoscopy is recommended, although some advocate a flexible sigmoidoscopy [8]. A repeat plain film of the abdomen is often warranted to ensure that no perforation took place during the extraction process many ingenious methods have been described in literature to extract rectal foreign bodies, including Foley catheter, Seng taken-Blakemore tube, obstetrical forceps and vacuum extractor [8]. The best method for the removal of a blunt object is to grasp to object using one of the clamps mentioned earlier or better yet, using the surgeon's hand depending on the laxity on the canal and the success of the anal block. If the patient has a lax anal sphincter, there is a good block and the patient is adequately sedated then the object is often easily. Some smooth foreign bodies create a seal with the rectal mucosa. In this case it has been shown that placing a Foley catheter alongside the balloon above it helps in extraction [8]. Should signs or symptoms of perforation or drug ingestion/ toxicity be observed, then exploratory laparotomy for removal of the remaining packets and aggressive medical treatment for the overdose is warranted. Flexible endoscopy is reserved for objects that are located more proximally in the rectum or the distal sigmoid colon. Endoscopy also provides excellent visualization of the mucosa to evaluate for subtle and gross changes in the rectal mucosa [9,10]. Endoscopy can serve as a middle ground in many cases to avoid surgical exploration by enabling evaluation and therapeutic removal of objects that may have been no amenable to transanal extraction. Once successful extraction has been accomplished, the endoscope should be passed again to evaluate the bowel mucosa for any inadvertent injuries [10].

If the local perianal block and sedation are unsuccessful in the emergency department, the patient needs to be brought to the operating room for a general or spinal anesthetic to aid in the removal of the object. After anesthesia has been applied and the patient is adequately relaxed, if the foreign body cannot be removed from below then a laparotomy is indicated. Surgery is also indicated in all patients who present with perforation (free air), sepsis, or peritonitis. Some surgeons have also described laparoscopy as an aid to push the object more distally into the rectum for a transanal removal [11]. The first step is to attempt to milk the object distally into the rectum. If this fails, then a colostomy and removal of the foreign object is needed. This colostomy can be primarily repaired. Diversion is reserved for patients with frank peritonitis and instability, perforation with extensive fecal contamination [7,8,11]. The most dangerous complication of a rectal foreign body is perforation. When patients present with a rectal perforation, they should at first be stabilized like any trauma patient. After stabilization, management depends on 3 factors: first, whether the patient is clinically stable or unstable, second, whether the perforation is in an intraperitoneal or extra peritoneal location, and last, whether there is significant fecal spoilage or not. A good rule of thumb is to manage a rectal perforation from a foreign body are diversion, debridement, distal washout, and drainage [7,11]. Unstable patients, those with multiple comorbidities, and those with significant tissue damage and de-layed presentation more often require a diversion.

Post removal observation depends on several factors, such as the clinical status of the patient, comorbidities, delay in presentation, and whether or not there was any resultant trauma to the rectum or surrounding tissue. Even with routine transanal extraction, the authors recommend several hours of close observation with serial abdominal examinations and plain films as indicated. Bleeding from lacerations in the rectal mucosa is generally self-limited. Death from sepsis and multisystem organ failure has been reported [11]. Traumatic disruption of the anal sphincter can result in mild to severe fecal incontinence, depending on the degree of the injury. Attempts for surgical correction of any sphincter injury should be delayed until adequate time has passed to evaluate any resultant defect and clinical symptoms.

Summary

Rectal foreign bodies present a difficult diagnostic and management dilemma. This is often because of the delayed presentation, wide variety of objects that cause the damage, and the wide spectrum of injury patterns that range from minimal extra peritoneal mucosal injury to free intraperitoneal perforation, sepsis, and even death. The evaluation of the patient with a rectal foreign body needs to progress in an orderly fashion, with appropriate examination, laboratory and radiographic evaluation, and resuscitation with intravenous fluids and antibiotics. In the no perforated stable patient, the object should be removed under sedation via the transanal approach. Surgery with a laparotomy should be reserved for patients with perforation or ischemic bowel or cases of failed transanal attempts. After removal of the foreign body, the authors suggest a period of observation, a rigid or flexible endoscopy to evaluate for rectal injury and repeat plain films to examine for evidence of injury and perforation that may have occurred during the extraction process. Patient was referred to the psychiatrist for his perversion disorder, which was also mandatory for preventing recurrences.

References

1. Kurer MA, Davey C, Khan S, Chintapatla S (2010) Colorectal foreign bodies: a systematic review. *Colorectal Dis* 12: 851-861. [Link: https://goo.gl/Wo5fbT](https://goo.gl/Wo5fbT)
2. Koomstra JJ, Weersma RK (2008) Management of rectal foreign bodies: Description of a new technique and clinical practice guidelines. *World J Gastroenterol* 14: 4403-4406. [Link: https://goo.gl/rs5Xtd](https://goo.gl/rs5Xtd)
3. Akhtar MA, Arora PK (2009) Case of unusual foreign body in rectum. *Saudi J Gastroenterol* 15: 131-132. [Link: https://goo.gl/161gVq](https://goo.gl/161gVq)
4. Goldberg JE, Steele SR (2010) Rectal foreign bodies. *SurgClin N Am* 90: 173-184. [Link: https://goo.gl/4xT7NS](https://goo.gl/4xT7NS)
5. Singaporewalla RM, Tan DEL, Tan TK (2007) Use of endoscopic snare to extract a large rectosigmoid foreign body with review of literature. *Surg Laparosc Endosc Percutan Tech* 17: 145-148. [Link: https://goo.gl/E3j5zt](https://goo.gl/E3j5zt)
6. Nivatvongs S, Metcalf DR, Sawyer MD (2006) A simple technique to remove a large object from the rectum. *J Am Coll Surg* 203: 132-133. [Link: https://goo.gl/H1QKMW](https://goo.gl/H1QKMW)
7. Cohen JS, Sackier JM (1996) Management of colorectal foreign bodies. *J R CollSurgEdinb* 41: 312-315. [Link: https://goo.gl/cqYYzo](https://goo.gl/cqYYzo)
8. Humes D, Lobo DN (2005) Removal of a rectal foreign body by using a Foley catheter passed through a rigid sigmoidoscope. *Gastrointest Endosc* 62: 610. [Link: https://goo.gl/FbL7h1](https://goo.gl/FbL7h1)
9. Billi P, Bassi M, Ferrara F, Biscardi A, Villani S, et al. (2010) Endoscopic removal of a large rectal foreign body using a large balloon dilator: report of a case and description of the technique. *Endoscopy* 42: E238. [Link: https://goo.gl/AKjFVM](https://goo.gl/AKjFVM)
10. Matsushita M, Shimatani M, Uchida K, Nishio A, Okazaki K (2009) Endoscopic removal of hollow colorectal foreign bodies with the use of a balloon catheter. *Gastrointest Endosc* 69: 604-605. [Link: https://goo.gl/6xmPc7](https://goo.gl/6xmPc7)
11. Arora S, Ashrafian H, Smock ED, Ng P (2009) Total laparoscopic repair of sigmoid foreign body perforation. *J Laparoendosc Adv Surg Tech A* 19: 401-403. [Link: https://goo.gl/VQBCF8](https://goo.gl/VQBCF8)