



Clinical Group

Global Journal of Medical and Clinical Case Reports

ISSN: 2455-5282

DOI

CC By

Manh Nguyen Huu, Dung Tran Trung*, Thanh Ma Ngoc, Quyet Tran, Trinh Le Khanh, Hanh Tran Thi My and Dat Tran Tien

Hanoi Medical University, Hanoi, Vietnam

Dates: Received: 09 November, 2017; Accepted: 14 November, 2017; Published: 15 November, 2017

***Corresponding author:** Dung Tran Trung, Hanoi Medical University, No. 1, Ton That Tung Street, Hanoi, Vietnam. Tel: +84-24-238523798; Fax: +86-24-38523798; E-mail: dungbacsy@dungbacsy.com

Keywords: Subacromial impingement syndrome; Corticoid injection

<https://www.peertechz.com>

Case Report

Corticoid Injection for Subacromial Impingement Syndrome Treatment

Abstract

Objective: Evaluate the treatment result of corticoid injection for subacromial impingement syndrome

Patients and method: 30 patients with shoulder pain for at least 3 months, diagnosed subacromial impingement syndrome, excluded rotator cuff tear and labral lesion. A single injection into subacromial space with Methylprednisolone acetate 40 mg. Evaluate the result with VAS and Constant score.

Results: Pre-injection average VAS is $8,4 \pm 1,25$; Post-injection VAS is $2,6 \pm 1,12$; Pre-injection average Constant score is $44,1 \pm 9,32$. Post-injection average Constant score is $61,2 \pm 10,34$. The difference between pre-injection and post-injection results is significant with $p < 0,05$.

Conclusion: Corticoid to subacromial space results in improving symptoms of pain and functional shoulder joint

Introduction

Shoulder impingement syndrome (subacromial impingement) is a clinical syndrome which occurs when the tendons of the rotator cuff muscles become irritated and inflamed as they pass through the subacromial space, the passage beneath the acromion [1,2]. The most common symptom is pain around the acromion and spreads to deltoid muscle. There are a lot of damage levels of shoulder impingement, including in a late-stage subacromial impingement often accompanies with rotator cuff tendon, and this syndrome is the main reason leading to rotator cuff tear [2]. On examination, the shoulder is slightly swollen around the acromion and coracoid process. Neer test and Hawkins test is a clinical sign to diagnose [2], furthermore Impingement test could diagnose and this test is described by Neer [1,3]. by the way using subacromial space anesthesia and if the patient is less painful, the test is positive. Corticosteroids injection is considered as a basic treatment for subacromial impingement [4-6]. This study aims to: Evaluate the results of shoulder impingement syndrome outcome by using local corticosteroid at Hanoi Medical University.

Material and methods

Methods: Prospective cohort study

Objectives: 30 patients coming to clinical at Hanoi Medical University Hospital from January 2010 to December 2012 with symptoms following:

- Shoulder pain for at least 3 months
- Positive test Impingement by lidocaine 1%
- No symptoms of shoulder instability and no symptoms of rotator cuff tears
- No limit of passive shoulder joint mobilization
- MRI shows no cartilage injury and rotator cuff injury

Methods: Prospective cohort study

Injection technique: Using methylprednisolone acetate 40mg (Depomedrol, Pfizer). Location: the later-posterior line at the level posterior ridge of the acromion. The patient is in sitting position, lose the hand to widen sub-acromial space. Sterilize and inject into space with a 25G sterilized syringe and a 1,5G needle. After injection, the patient slightly moves and does not ride a bike, motorbike, carry heavy things in the first week. Shoulder exercises increase gradually (Figure 1)

Evaluate the results by VAS and Constant (shoulder function) after 1 month of treatment.

Results

Comment: The proportion of female is a majority, the average age is 52,9. The duration of symptoms till treatment is 11,5. The right shoulder injury is prevalent (Table 1).

Comment: The outcome of patients based on VAS score and Constant score after treatment significantly improve (Table 2).

Discussion

In table 1, the majority of patients were female, accounts for 60%. The average age was $52,3 \pm 6,84$ years old. Many studies of other authors also pointed out that middle-age occupies a majority and female is prevalent [1,3,4]. De Quervain syndrome and hurt finger springs often occur in female and middle-age as well as other lesions of tendon and synovial fluid because of the same mechanism [5]. Other factors are referred as a shoulder injury, we saw 6 cases, 4 males and 2 females. Injuries are considered as great factors and the onset of the damage. The mechanism of shoulder impingement syndrome was described by Neer in 1972 [1].

The majority of pain happens on the right shoulder. Some authors reported the same results or equivalent between 2 positions but they have not shown a significant difference or relevant factors yet [3,4].

Clinical symptoms of this injury are usually painful, pain increases when movement. The location of pain is unclear, around the acromion and coracoid, may be spread to deltoid muscle. The etiology of pain is rubbing of supraspinatus tendon between great tubercle, acromion and coracoacromial

ligament, then the onset of inflammation process of synovial fluid at subacromial space [2]. In early stages, this syndrome does not have rotator cuff injury and this is an important factor related to treatment indications. Besides clinical examination, Lidocaine test injection to subacromial space to evaluate is called Impingement test which helps to diagnose shoulder impingement syndrome.

Results of treatment accessed by VAS and Constant showed an improvement after treatment with a statistically significant difference. The earliest improvement happens 3 days after injection and it maintains for 2 weeks. Pain symptoms of all patients are almost complete, no expression of inflammatory pain when moving, some patients show signs of mild discomfort when heavy exercises. Movement range improves much compared to pre-surgery based on increasing Constant score. Our results are appropriate to other authors [3,4].

There are several methods to treat shoulder impingement syndrome such as medication, physical therapy, oriental treatment, local injection, arthroscopy or surgery and so on [1,5,8]. In which surgery is often performed in late-stage, much degeneration, rotator cuff tears which requires surgery such as suture the tendon tears, take out degenerated issues and sub-acromial space plasty [1]. Internal medicine is indicated at early-stage when no tendon injury and no mechanical narrow space [4-6]. The patients who we indicated to treatment with hard criteria, was diagnosed by the clinical test, positive test Impingement, ultrasound and MRI to confirm the diagnosis and exclude rotator cuff tear, cartilage rim tear. Patient selection with above criteria have a good outcome and clearly improve compared to pre-surgery based on VAS score and Constant score.

Using local Corticoid injection was accepted in a majority of author due to the effective treatment and less systemic adverse side effects [4-6], some authors reported some local adverse side effects on rotator cuff tendon but not much, especially only one injection and using methylprednisolone[6,9]. Injection technique is an interesting problem, some researchers showed that 21% of injection is unsatisfied anatomy require, means we injected medicine to deltoid muscle, not subacromial space [7,8], and then suggested the injection under ultrasound [10], and showed the exact results, as well as better, improve as. However, in reality, we did not have an ultrasound at clinical examination room and we performed surgery and arthroscopy into subacromial space achieving a high outcome based on individual experience. Naredo et al. [10]. Showed that the group of injection without ultrasound guidance depending significantly on the experience of the doctor.

Conclusion

We conducted a research with 30 patients of shoulder impingement syndrome by injecting Corticoid to subacromial space results in improving symptoms of pain and functional shoulder joint, and the change of VAS and Constant has a statistically significant difference.

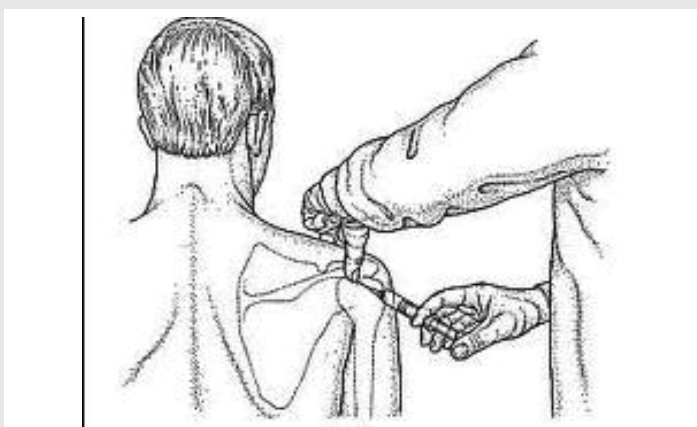


Figure 1: Illustration of injection into subacromial space technique [7].

Table 1: Patient characteristics.

Patient characteristic	N	%	
Gender	Male	12	40%
	Female	18	60%
Average age	$52,3 \pm 6,84$ (23 – 67)		
Location of shoulder injury	Right	19	63,3%
	Left	11	36,7%
The duration of symptoms till treatment	$11,5 \pm 8,92$ (3 – 24 months)		

Table 2: Treatment results.

Results	Pre-surgery	Post-surgery	P
Constant score	$44,1 \pm 9,32$	$61,2 \pm 10,34$	< 0,05
VAS score	$8,4 \pm 1,25$	$2,6 \pm 1,12$	< 0,05

References

1. Neer CS II (1972) Anterior acromioplasty for the chronic impingement syndrome in the shoulder: a preliminary report. *J Bone Joint Surg* 54: 41-50. [Link: https://goo.gl/Lh7yJq](https://goo.gl/Lh7yJq)
2. Matsen AF III, Arntz CT, Lippitt SB (1998) Rotator cuff. In: Rockwood CA Jr, Matsen AF III, editors. *The shoulder*. 2nd ed. Philadelphia: W. B. Saunders 755-840
3. Plafki C, Steffen R, Willburger RE, Wittenberg RH (2000) Local anaesthetic injection with and without corticosteroids for subacromial impingement syndrome. *Int Orthop* 24: 40-42. [Link: https://goo.gl/ZYdHB3](https://goo.gl/ZYdHB3)
4. Blair B, Rokito AS, Cuomo F, Jarolem K, Zuckerman JD (1996) Efficacy of injections of corticosteroids for subacromial impingement syndrome. *J Bone Joint Surg* 78: 1685-1689. [Link: https://goo.gl/sn4aJM](https://goo.gl/sn4aJM)
5. White RH, Paull DM, Fleming KW (1986) Rotator cuff tendinitis: comparison of subacromial injection of a long acting corticosteroid versus oral indomethacin therapy. *J Rheumatol* 13: 608-613. [Link: https://goo.gl/ss6qVm](https://goo.gl/ss6qVm)
6. Buchbinder R, Green S, Youd JM (2003) Corticosteroid injections for shoulder pain. *Cochrane Database Syst Rev*. [Link: https://goo.gl/TT3EnK](https://goo.gl/TT3EnK)
7. Esenyel CZ, Esenyel M, Yesiltepe R, Ayanoglu S, Bulbul M, et al. (2003) The correlation between the accuracy of steroid injections and subsequent shoulder pain and function in subacromial impingement syndrome. *Acta Orthop Traumatol Turc* 37: 41-45. [Link: https://goo.gl/w4sLQS](https://goo.gl/w4sLQS)
8. Yamakado K (2002) The targeting accuracy of subacromial injection to the shoulder: an arthrographic evaluation. *Arthroscopy* 18: 887-891. [Link: https://goo.gl/VxGPYn](https://goo.gl/VxGPYn)
9. Akpınar S, Hersekli MA, Demirors H, Tandogan RN, Kayaselcuk F (2002) Effects of methylprednisolone and betamethasone injections on the rotator cuff: an experimental study in rats. *Adv Ther* 19: 194-201. [Link: https://goo.gl/9vTMEJ](https://goo.gl/9vTMEJ)
10. Naredo E, Cabero F, Beneyto P, Cruz A, Mondejar B, et al. (2004) A randomized comparative study of short term response to blind injection versus sonographic-guided injection of local corticosteroids in patients with painful shoulder. *J Rheumatol* 31: 308-314. [Link: https://goo.gl/GsAsNR](https://goo.gl/GsAsNR)