

Case Report

Giant Umbilical Hernia in a Patient with Hurler's Syndrome: Case Report and Management Principles

M Lahfaoui* and H Benhaddou

Department of Pediatric Surgery, University of Mohammed VI, Oujda, Morocco

Received: 23 March, 2020

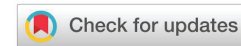Accepted: 30 April, 2020

Published: 01 May, 2020

***Corresponding author:** M Lahfaoui, Department of Pediatric Surgery, University of Mohammed VI, Oujda, Morocco, Tel: +212676566472; E-mail: mohammedlahfaoui@gmail.com

Keywords: Howler's syndrome; Giant umbilical hernia; Mucopolysaccharidosis

<https://www.peertechz.com>



Abstract

The surgical and anesthetic management of patients with giant umbilical hernia associated with Hurler's disease is a challenge due to the many problems. We present a recent case of giant umbilical hernia with skin necrosis accompanying Hurler's syndrome. In addition, a literature review was conducted using the PubMed, Embase, Ovid, Scopus and Cochrane databases. The literature review identified 3 children documented in 3 publications throughout history. The observation we report proves that the umbilical hernia accompanying Hurler's syndrome can reach an impressive size with a risk of complication, making surgical repair very difficult with a high risk of recurrence. Spinal anaesthesia is contraindicated due to the associated spinal malformations. Laryngoscopy and fibre-optic bronchoscopy can be used for intubation in difficult cases, and the laryngeal mask has proven to be a useful additional aid. Despite the risk, surgical repair is mandatory.

Introduction

Hurler's syndrome is a genetic disorder that results in the accumulation of glycosaminoglycans (formerly known as mucopolysaccharides) due to a deficiency of alpha-L iduronidase. The surgical and anesthetic management of patients with giant umbilical hernia associated with Hurler syndrome is a challenge due to numerous medical problems, including staturweight retardation, dysmorphic facies, airway obstruction, heart disease, hepato-splenomegaly and severe joint restriction [1]. Fiber optic laryngoscopy will be used for intubation due to the abnormal anatomy of the larynx. Umbilical and inguinal hernias are common in this pathology, and are generally treated conservatively unless complications arise, given the rarity of the latter such as incarceration and the risks associated with surgical correction are high [2]. We present our experience and discuss the different anesthetic and surgical problems in the management of a giant umbilical hernia in a patient with Hurler's syndrome.

Case report

An 11 year old girl with Hurler's syndrome presented with a giant umbilical hernia 31*22 cm in diameter with skin necrosis

opposite (Figure 1). An abdominal CT scan was performed: it objectified an umbilical hernia with a 19 cm fascia defect (Figure 2). The hernia was repaired under general anaesthesia. Ordinary intubation failed due to abnormal laryngeal anatomy, which necessitated laryngoscopic intubation by fibre optic. Through a circular skin incision, the hernia sac was dissected, the fascia defect (19 cm) was closed mainly with superimposed layers using separate points with a non-resorbable thread and the placement of a two-sided prosthetic plate (Figure 3). Finally, elastoplast was used to reinforce the abdominal wall (Figure 4). The postoperative follow-up was uneventful (Figure 5) and the patient was discharged 15 days after admission. Six months after the operation, the patient was well without any sign of recurrence. This surgical repair nevertheless improved the quality of life of the girl and limited the progression of the disease. Unfortunately, the patient died 18 months later due to respiratory complications related to HURLER syndrome.

Discussion

Mucopolysaccharidoses (MPSs) consist of a rare group of inherited lysosomal storage diseases, specifically related to glycosaminoglycan (GAG) metabolism defects. Each type of MPS is caused by deficiency of a specific enzyme involved in

the degradation of GAGs, causing accumulation of partially degraded products. MPS is estimated to affect one in every 20,000 live births [3,4]. The observation we report proves that the umbilical hernia accompanying Hurler's syndrome can reach an impressive size with a risk of complication, which leads us to reconsider the abstentionist attitude in some cases. The arguments that have motivated surgical treatment are mainly represented by the volume of the hernia, the risk of strangulation and the significant functional impairment [5]. Surgical treatment can be a laborious process. Airway management can be difficult due to macroglossia and short neck with limited mobility [6]. The trachea may be narrow, the soft tissues are swollen and bleed easily, and these patients are susceptible to bronchospasm. Spinal anesthesia is contraindicated because of the associated spinal malformations. Laryngoscopy and fiber-optic bronchoscopy may be used for intubation. In difficult cases, the laryngeal mask has been shown to be a useful additional aid [7]. Yeung

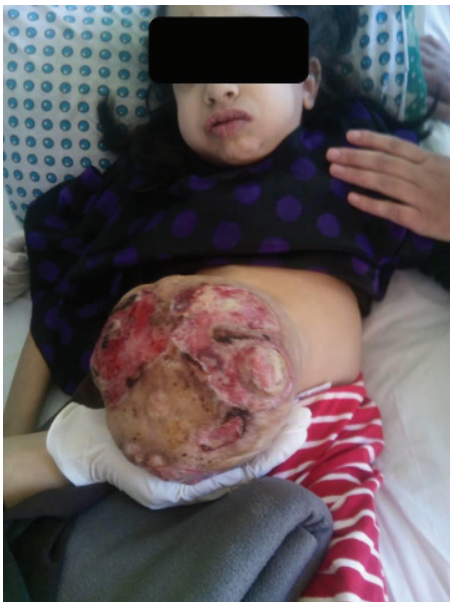

Figure 1: Giant umbilical hernia around with ischemic skin changes in a patient with Hurler's syndrome.

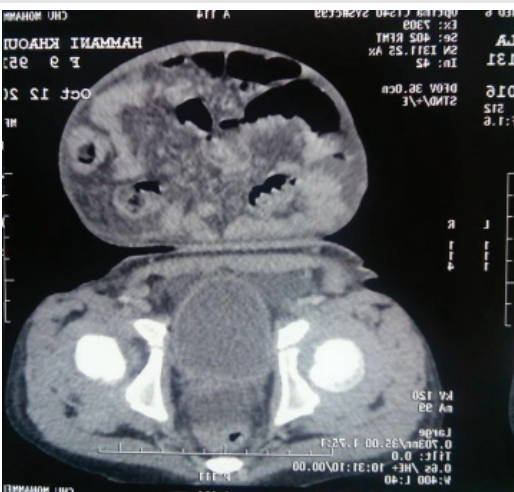


Figure 2: Abdominal CT-Scan showed a hug umbilical hernia with fascia defect of 31cm.

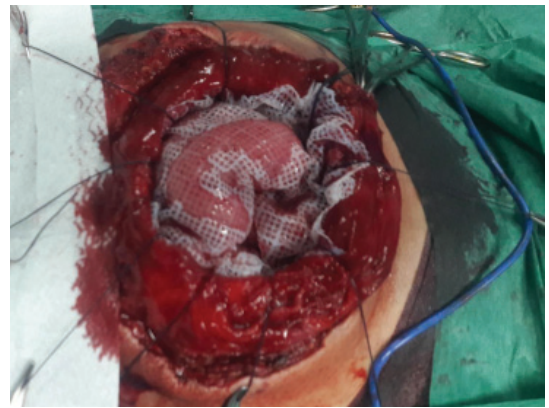


Figure 3: Peroperative Picture .

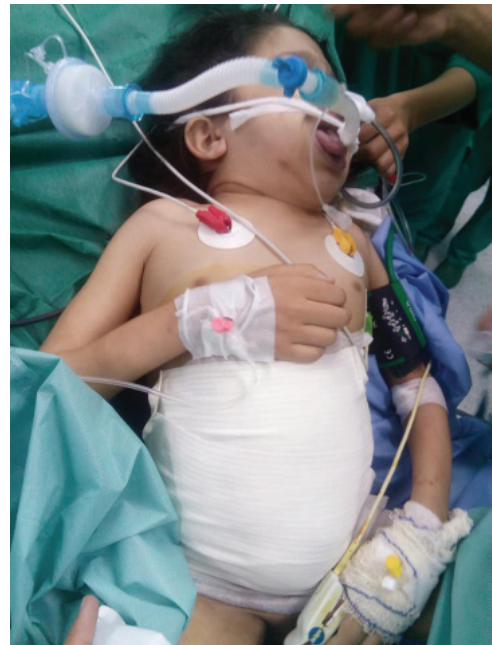

Figure 4: Picture immediately after the surgical operation.

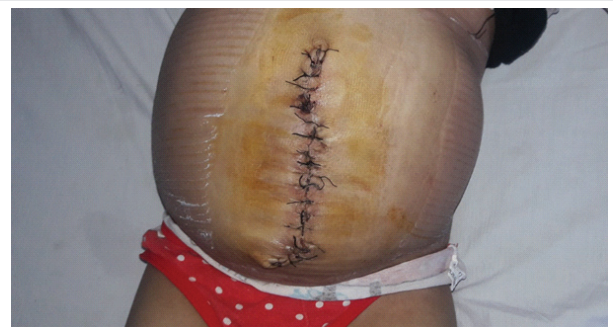

Figure 4: Picture immediately after the surgical operation.

et al. (2009) used flexible fiberoptic laryngoscopy (FFL) and polysomnography (PSG) to assess some patients with different types of MPS. They found that 19 of their 27 patients presented with upper airway obstruction. Of these 19 patients, seven were submitted to PSG and had an AHI between 10 and 17. Only five of the patients were submitted to direct laryngoscopy, which revealed the presence of macroglossia and of redundant tissues



in the oropharynx and in the supraglottis [8]. We chose to use a prosthetic plate as part of the repair because the parietal defect is too large to restore normal anatomy and to avoid the risk of recurrence.

How to choose a prosthesis?

The choice to use a particular type of prosthesis depends on many factors:

- The state of the wall: can an optimal treatment be achieved by restoring the normal anatomy with a median white line thus ensuring a good dynamic of the abdominal wall muscles. In these conditions, the prosthesis is used as a reinforcement. In the opposite case, especially in the case of a too important parietal defect, the prosthesis comes to patch the loss of substance. There will certainly not be any more post-operative venting, but the quality and tone of the abdominal strap will not have been restored.
- choice of surgical technique: laparoscopy almost always requires the use of an intraperitoneal prosthesis;
- Patient's condition: the septic risk of an emergency operation formally contraindicates the use of a non-absorbable prosthesis;

- surgeon's preferences: intraperitoneal prosthesis avoiding large detachments but exposing to the risk of adhesions or subperitoneal prosthesis, a classic technique but long and more difficult [9].

The aim of a prosthesis placed outside the peritoneal cavity is to reinforce the long-term solidity of the wall, by acting as a support for collagen healing. This desired incorporation imposes the use of macroporous prostheses. Fixation of the prosthesis is only useful for the time of this incorporation and can therefore be done with slow resorption wire. The choice is vast between Dacron (Mersilene®, Parietex®) and polypropylene with almost similar results. The choice depends on each person's habits. For our part, and in the light of our experience of more than 10 years, we remain faithful as soon as possible to Mersilene® placed in a pre-peritoneal retro-muscular site [9,10] (Table 1).

Conclusion

Despite the risk, it is mandatory to perform elective hernia repair using a prosthetic plate in some cases of Hurler's syndrome, emphasizing strict adherence to the principles of anesthetic, logistical (choice of plate type) and surgical management.

Table 1: Complete literature review for patients with umbilical hernia attained from the hurler syndrome.

Publication	Age/sex	Symptoms of the disease	Surgical History	Radiology	Surgery	Complications and follow-up
[6]	3, F	Perforation of a congenital umbilical hernia	none	Undocumented.	The fascia defect (2 cm) was closed mainly by superimposing layers with simple absorbable sutures.	Six months later, the hernia reappeared. Laparoscopic hernia correction with insertion of a 10 15 cm PTFE prosthetic plate.
[5]	15, M	Strangulation of a congenital umbilical herni.	none	Undocumented.	A defect of 3x3 cm was repaired by Mayo's technique.	None. Duration of follow-up not mentioned.
[10]	14, F	A giant strangulated umbilical hernia about 18 cm in diameter.	none	PSA + Abdominal CT	The fascia defect (8cm) was closed... mainly with overlapping layers using non-absorbable sutures with insertion of a prosthetic plate.	None. Follow-up at six months.
Notre observation 2020	11, F	A giant strangulated umbilical hernia of about 31*22 cm in diameter.	none	abdominal CT scan	The fascia defect (19 cm) was closed... mainly with overlapping layers using non-absorbable sutures with insertion of a Mersilene® prosthetic plate	None. Follow-up at 1 year.

References

1. Prakash S, Gupta P, Mullick P, Gogia AR (2006) Anaesthetic management of a child with mucopolysaccharidoses. *Indian J Anaesth* 50: 220-222. [Link: https://bit.ly/2y84vUx](https://bit.ly/2y84vUx)
2. Gopinath G, Nagaraj P, Kulkarni ML (2005) Obstructed umbilical hernia in a child with Hurler's syndrome. *Indian J Surg* 67: 49-51. [Link: https://bit.ly/3bX2FEk](https://bit.ly/3bX2FEk)
3. McKunsick VA, Neufeld EF (1983) The mucopolysaccharidoses storage

diseases. In: Stanbury JB, Wyngaarden JB, Fredrickson DS, editors. *The metabolic basis of inherited diseases*. 5. New York: McGraw-Hill 342-365.

4. Kakkis E, Wynn R (2015) *Mucopolysaccharidoses: clinical features and diagnosis*. UpToDate. Wolters Kluwer Health. [Link: https://bit.ly/2YmStkH](https://bit.ly/2YmStkH)
5. Belani KG, Krivit W, Carpenter B, Braulin E (1993) Children with mucopolysaccharidoses: perioperative care, morbidity, mortality, and new findings. *J Pediatr Surg* 28: 403-410. [Link: https://bit.ly/3f5TdAx](https://bit.ly/3f5TdAx)
6. Hulsebos RG, Zeebregts CJ, de Langen ZJ (2004) Perforation of a congenital



umbilical hernia in a patient with Hurler's syndrome. J Pediatr Surg 39: 1426-1427. [Link: https://bit.ly/2WhcgjF](https://bit.ly/2WhcgjF)

7. Walker RW, Allen DL, Rothera MR (1997) A fibreoptic intubation technique for children with mucopolysaccharidoses using the laryngeal mask airway. Paediatr Anaesth 7: 421-426. [Link: https://bit.ly/3d5P6mh](https://bit.ly/3d5P6mh)
8. Yeung AH, Cowan MJ, Horn B, Rosbe KW (2009) Airway management in children with mucopolysaccharidoses. Arch Otolaryngol Head Neck Surg 135: 73-79. [Link: https://bit.ly/2yXaMIO](https://bit.ly/2yXaMIO)

9. Bouillot JL, Servajean S, Pozzo A, Akkash Y (2003) Éventrations de la paroi abdominale. Rev Prat 53: 1677-1682.

10. Ait Yahia S, Sayah C, Soualili Z (2016) Giant Umbilical Hernia in a Patient with Hurler's Syndrome: Case Report and Management Principles iMedPub Journals 2: 14. [Link: https://bit.ly/2zOmzqV](https://bit.ly/2zOmzqV)

Discover a bigger Impact and Visibility of your article publication with Peertechz Publications

Highlights

- ❖ Signatory publisher of ORCID
- ❖ Signatory Publisher of DORA (San Francisco Declaration on Research Assessment)
- ❖ Articles archived in worlds' renowned service providers such as Portico, CNKI, AGRIS, TDNet, Base (Bielefeld University Library), CrossRef, Scilit, J-Gate etc.
- ❖ Journals indexed in ICMJE, SHERPA/ROMEO, Google Scholar etc.
- ❖ OAI-PMH (Open Archives Initiative Protocol for Metadata Harvesting)
- ❖ Dedicated Editorial Board for every journal
- ❖ Accurate and rapid peer-review process
- ❖ Increased citations of published articles through promotions
- ❖ Reduced timeline for article publication

Submit your articles and experience a new surge in publication services
(<https://www.peertechz.com/submit>).

Peertechz journals wishes everlasting success in your every endeavours.

Copyright: © 2020 Lahfaoui M, et al. This is an open-access article distributed under the terms of the Creative Commons Attribution License, which permits unrestricted use, distribution, and reproduction in any medium, provided the original author and source are credited.