

Received: 29 April, 2021

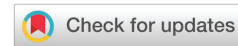Accepted: 08 May, 2021

Published: 10 May, 2021

\*Corresponding author: Magdalena Chrapkowska, Department of Forensic Medicine, Pomeranian Medical University, al. Powstańców Wielkopolskich 72, 70-111 Szczecin, Poland, E-mail: [magdachrapkowska@mp.pl](mailto:magdachrapkowska@mp.pl)

Keywords: Carotid artery stenting; Carotid stent thrombosis; Kinking

<https://www.peertechzpublications.com>



## Case Report

# Acute thrombosis during carotid artery stenting caused by stent-induced kinking

Magdalena Chrapkowska<sup>1\*</sup> and Andrzej Modrzejewski<sup>2</sup>

<sup>1</sup>Department of Forensic Medicine, Pomeranian Medical University, Szczecin, Poland

<sup>2</sup>Department of General Surgery, Pomeranian Medical University, Szczecin, Poland

## Abstract

A case of a 71-year-old man with previous Transient Ischemic Attack (TIA), treated with stent implantation due to right internal carotid artery stenosis. The procedure was complicated by stenosis and kinking of the vessel distal to the stent and thrombus formation. The flow in the stented artery was not restored. A massive stroke occurred. The man died on the 3rd day after the procedure.

## Introduction

Carotid artery angioplasty with stent implantation (CAS) is used to treat symptomatic ICA (internal carotid artery) stenosis. Like any endovascular intervention, CAS is fraught with the risk of complications such as in-stent thrombosis. We present a case complicated by kinking with acute in-stent thrombosis. This complication is very rare.

## Case report

A 71-year-old man was admitted to the vascular surgery department for a right carotid artery CAS procedure. The patient had suffered a TIA confirmed by CT scan 4 months earlier. On head CT scan, a hypodense area of 12x8 mm was described within the right hemisphere near the lateral ventricle. Ultrasound-doppler and angio-CT of the intracerebral arteries were performed to diagnose the causes of TIA. The following abnormalities were described on ultrasound-doppler: no flow in left internal carotid artery (LICA), flow acceleration in the left external carotid artery to 234 cm/second, PI – 2,58 (*pulsatility index*), flow acceleration in the Right Internal Carotid Artery (RICA) to 264 cm/second, PI – 1,19 and normal flow in the right external carotid artery. During angio-CT, both common carotid arteries were visualized, and both were unobstructed. Further described full length obstruction of the LICA, a critical stenosis in the proximal segment of the RICA of 7 mm and both vertebral

arteries without stenosis. The descriptions of the above studies did not diverge from the typical anatomy of this area.

On the day of admission, the neurological examination showed no abnormalities. The man was qualified for CAS surgery. On the day before the procedure, basic laboratory tests were performed, all coagulation parameters were within normal limits. On that day dalteparin in a dose of 5 thousand units was administered subcutaneously.

The stent implantation procedure was performed by a specialist in vascular surgery. Access was obtained through the right femoral artery, with the use of a cerebral protection filter (Emboshield). Xact 9-7mm/30 mm stent (Abbott) was implanted, followed by 5x20 mm balloon postdilatation. Arteriography showed vessel kinking and 75% RICA stenosis distal to the stent. The images showed loss of contrast filling of the artery, indicating thrombus formation inside the stent (Figure 1). The man was transported to the vascular surgery department with the recommendation of an urgent head CT scan and neurological consultation. A continuous infusion of Heparin 10 thousand j/24h was ordered.

After the procedure, a head CT was performed. Cerebral CT revealed a hyperdense right middle cerebral artery and a stroke in the right cerebral hemisphere. Doppler ultrasound of the carotid arteries was not ordered. No action was taken to restore flow in the stented vessel.



The patient's condition gradually deteriorated. Six hours after the procedure, the patient was not cardiovascularly and respiratory efficient. On the third day after the procedure, the man died.

## Discussion

The patient requires close monitoring of the neurological status during and after the procedure. Any deterioration of this condition requires urgent intervention. Two methods of monitoring are recommended in the literature. One is ultrasound-Doppler examination. This test is inexpensive and readily available in most hospitals. The other recommended is angio-CT. CT angiography visualizes the extracranial vessels that supply blood to the brain and the vessels that remain beyond the reach of ultrasound. In most hospitals, this examination is also available without unnecessary delay [1-3].

In this case, preoperative studies showed no deviation from standard carotid vascular anatomy. In the early stages of CAS, RICA kinking was observed during arteriography (Figure 2). In the later stage of the procedure, after stent insertion, the kinking intensified (migrated above the stent). This resulted in significant constriction of the vessel lumen. In addition, a thrombus formed in the stent (Figure 1). Such complications are very rare and few similar cases have been described.

The type of stent used, as well as its length, may have been the reason for this condition. Both open- and closed-cell stents are available. Each of these types has different properties. No correlation has been shown between the type of stent design and the incidence of acute stent thrombosis. However, it has been noted that open-cell stents are more flexible and adapt more easily to the shape of tortuous vessels. In case of a tortuous vessel, the use of a closed-cell stent may increase the risk of vessel kinking distal to the stenosis, which directly leads to thrombus formation inside the stent [4]. In the above

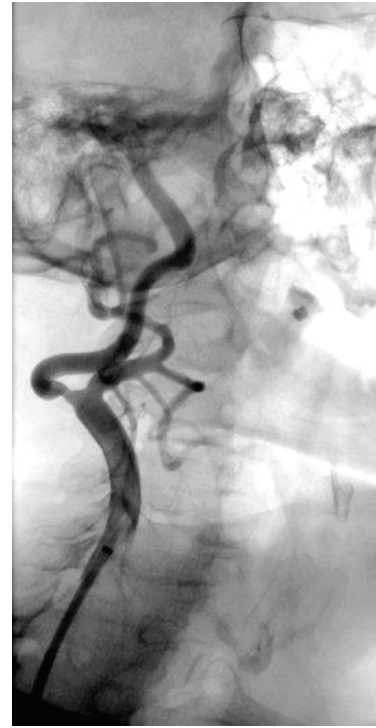

Figure 2: Internal carotid stenosis before carotid artery stenting procedure.

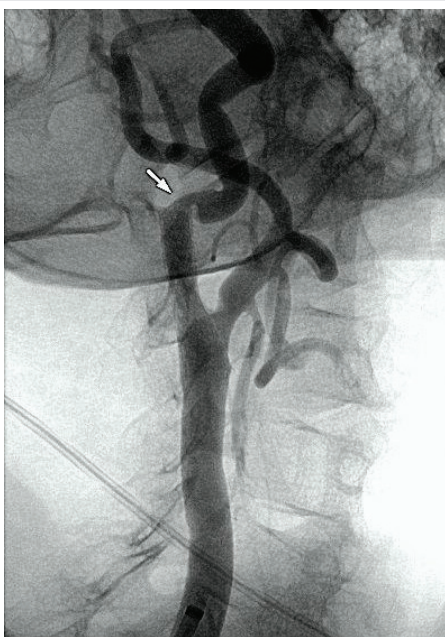


Figure 1: Stenosis of the RICA above the stent and vessel kinking.

clinical case, a 30mm XACT closed-cell stent was used. It is possible that the use of a shorter open-cell type stent could have prevented the incidence of kinking.

So far, the literature does not contain any recommendations on the management of CAS complicated by kinking-induced stent thrombosis. Advice on how to handle when such a complication occurs can only be found in published clinical cases. Konstantinos, et al. [2] reported a patient who developed carotid stent thrombosis 1 hour after CAS. This was caused by kinking in the distal part of the ICA. Emergency thromboaspiration was performed, resulting in partial recanalization of the vessel. Next, an urgent surgical revision with carotid eversion endarterectomy and stent removal was performed. As a result of the interventions, blood flow to the brain was restored.

## Conclusion

The type of stent used in carotid artery angioplasty should be adapted to the anatomy of the vessel. Observation of the patient's neurological status during the procedure as well as in the first hours after the procedure enables detection of early complications such as stent thrombosis. Delaying carotid revascularization creates a risk of stroke.

## References

1. Naylor AR, Ricco JB, de Borst GJ, Debus S, de Haro J, et al. (2018) Management of Atherosclerotic Carotid and Vertebral Artery Disease: 2017 Clinical Practice Guidelines of the European Society for Vascular Surgery (ESVS). *Eur J Vasc Endovasc Surg* 55: 3-81. [Link: https://bit.ly/3uy491a](https://bit.ly/3uy491a)
2. Moulakakis KG, Mylonas SN, Lazaris A, Tsvigoulis G, Kakisis J, et al. (2016) Acute Carotid Stent Thrombosis: A Comprehensive Review. *Vasc Endovascular Surg* 50: 511-521. [Link: https://bit.ly/3fc4i4a](https://bit.ly/3fc4i4a)



3. Coelho AP, Lobo M, Nogueira C, Gouveia R, Campos J, et al. (2019) Overview of evidence on risk factors and early management of acute carotid stent thrombosis during the last two decades. *J Vasc Surg* 69: 952-964. [Link: https://bit.ly/3o4wmKt](https://bit.ly/3o4wmKt)

4. Setacci C, de Donato G, Setacci F, Sirignano P, Galzerano G, et al. (2013) Tips and tricks to avoid periprocedural neurological complications in carotid artery stenting. *J Cardiovasc Surg (Torino)* 54: 11-21. [Link: https://bit.ly/2QXoZIZ](https://bit.ly/2QXoZIZ)

### Discover a bigger Impact and Visibility of your article publication with Peertechz Publications

#### Highlights

- ❖ Signatory publisher of ORCID
- ❖ Signatory Publisher of DORA (San Francisco Declaration on Research Assessment)
- ❖ Articles archived in worlds' renowned service providers such as Portico, CNKI, AGRIS, TDNet, Base (Bielefeld University Library), CrossRef, Scilit, J-Gate etc.
- ❖ Journals indexed in ICMJE, SHERPA/ROMEO, Google Scholar etc.
- ❖ OAI-PMH (Open Archives Initiative Protocol for Metadata Harvesting)
- ❖ Dedicated Editorial Board for every journal
- ❖ Accurate and rapid peer-review process
- ❖ Increased citations of published articles through promotions
- ❖ Reduced timeline for article publication

**Submit your articles and experience a new surge in publication services**  
(<https://www.peertechz.com/submission>).

*Peertechz journals wishes everlasting success in your every endeavours.*

**Copyright:** © 2021 Chrapkowska M, et al. This is an open-access article distributed under the terms of the Creative Commons Attribution License, which permits unrestricted use, distribution, and reproduction in any medium, provided the original author and source are credited.